

Blade implants in the rehabilitation of severely atrophic ridges

L Dal Carlo^{1*}, LI Linkow², ME Pasqualini³, M Shulman⁴, L Grivet Brancot⁵, M Nardone M⁶

Abstract

Introduction

The conception of the endosseous blade implant arose from the intuitions of Leonard I. Linkow (L.I.L.) and Ralph Roberts. Given the thinness of the blade, this implant can be used in any alveolar crest, but it is particularly useful in the thinnest, where the use of root-form implants is difficult and needs bone regeneration procedures. The aim of this paper was to discuss the use of blade implants in the rehabilitation of severely atrophic ridges.

Methodology

This report involved five centres located throughout the Italian country from 1972 to 2012. The clinicians used a specific surgical protocol; in some cases a variation of the original technique was used like 'endosseous distal extension' for the treatment of lower posterior sectors in the presence of low-density bone. In presence of satisfactory primary stability, the blade implants were loaded immediately.

Discussion

The blade implant allows for a simple surgical technique to be performed with standard instruments, valorisation of existing tissue and can be used without bone expansion and regeneration procedures. Also, it is possible the mechanical correction of parallelism issues during implant surgery and the blade implant can be

immediately loaded if adequate stability has been achieved.

Conclusion

The blade implant is an effective therapeutic device that is useful in the implant and prosthetic rehabilitation of severely atrophic ridges with a reduced trabecular component, especially, in the lower posterior sectors. The distally extended type can be employed in the posterior sectors, both upper and lower, while in the front aesthetic area and in the lateral sectors the blade can be used when an alternative device would entail less predictable and more invasive procedures. The response of the soft tissues surrounding this type of implant is excellent.

Introduction

The blade implant was devised by the ingenuity of L.I.L. and Ralph Roberts, but it was L.I.L. who first introduced it in clinical practice. After presentation of his implant to the Scientific Community in 1967, the following year he started to publish the results of studies on these implants to treat edentulism^{1,2}. Since then, thousands of patients have undergone prosthetic rehabilitation procedures with this type of implant.

Given its reduced thickness of ~1.6 mm, the blade implant is specifically indicated in the case of atrophic ridges, where conical or cylindrical implants cannot be placed without prior regenerative procedures³⁻⁵. The blade implant makes it possible to achieve the so called 'tricorticalism', i.e., contact with the inner, outer and basal cortical bone.

The original blades of L.I.L. had a pre-fabricated fixed abutment, which differed according to the region in which the implant had to be inserted.

In 1972, Ugo Pasqualini⁶ presented a 'polymorphic' blade implant with a screw-in abutment, which could be adapted to the anatomical conditions most commonly found in clinical practice (Figures 1 and 2).

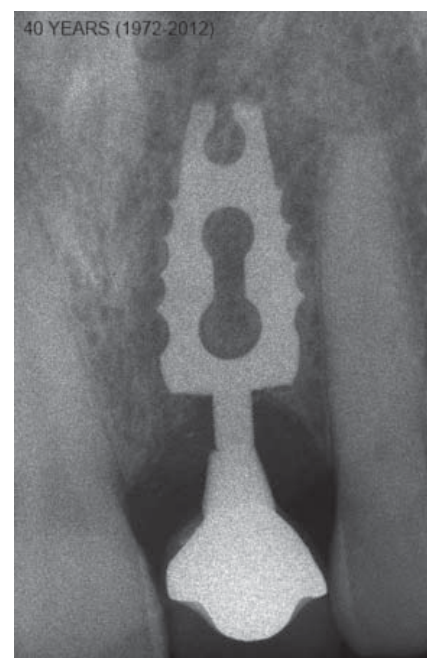


Figure 1: X-ray of a Pasqualini blade implant 40 years after placement in the left upper incisal area in 1972 - shows the healthy status of the bone surrounding a blade implant after 40 years of use.

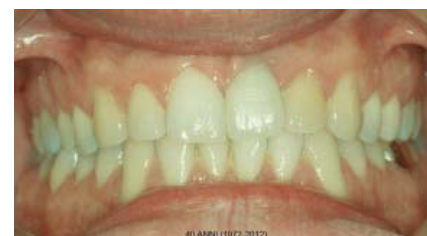

Figure 2: Image of a crown anchored on a Pasqualini blade implant 40 years after placement in the left upper incisal area in 1972.

*Corresponding author
Email: lucadalcarlo@yahoo.it

¹Private practice, Venice, Italy

²Perpetual NYU chair in Implant Dentistry, New York, USA

³Private practice, Milan, Italy

⁴Private practice, Cliffside Park, New Jersey, USA

⁵Private practice, Torino, Italy

⁶Medical Officer, Italian Ministry of Health, Rome, Italy

Regarding the implant shape and the prosthetic components, in the following years, many authors presented 'variations on the theme', thus proposing different types of emergent, semi-emergent or buried implants^{7,8}. The choice between immediate or delayed loading protocol is related to the bone quality of the implant site^{9,10}. This paper discusses the blade implant used in the rehabilitation of atrophic ridges.

Methodology

The authors have referenced some of their own studies in this methodology. These referenced studies have been conducted in accordance with the Declaration of Helsinki (1964), and the protocols of these studies have been approved by the relevant ethics committees related to the institution in which they were performed. All human subjects, in these referenced studies, gave informed consent to participate in these studies.

During the period between 1989 and 2013, in five Italian private dental centres around 1,000 patients were treated with blade implants whose post-operative and long-term course has been monitored. Average age of the patients was 58.2 years; female patients were 63.1%, while male patients were just 36.9%. Surgeons have used 605 blade implants in 518 anatomical sites. Each inserted implant was monitored over time.

Before treatment, the clinicians informed patients about the surgical procedures. A careful clinical history was performed to determine the general health status; radiographic (x-rays intra-oral and orthopantomogram) and CT scans were performed when indicated.

The protocol for placement of blade implants was:

- Creation of a flap wide enough to allow good visibility of the bone ridge;
- Drilling of a series of small holes in the alveolar ridge;

- Connection of the drilled holes while preparing the implant site, the depth of which should be consistent with blade height;
- Adjustment of the inclination of the abutment with respect to the antagonist tooth;
- Adaptation of the implant shape to anatomical conditions, where necessary;
- Proper placement of the blade in the osteotomy, with the implant shoulder 2 mm below the surface of the alveolar ridge.

The technique¹¹ requires instruments for minimally invasive surgery and, in some cases, the use of piezosurgery. Pneumatic tools can also be employed in order to achieve optimal press-fit conditions.

Using a multi-blade drill with a diameter of 0.9–0.1 mm, cooled with saline solution, a series of holes were prepared on the alveolar ridge (Figure 3), which connected to create the implant site (Figure 4). An alternative method entails the use of a piezoelectric knife. In very thin ridges, the use of bone chisels to prepare the implant site can help preserve the bone tissue. The mesiodistal width

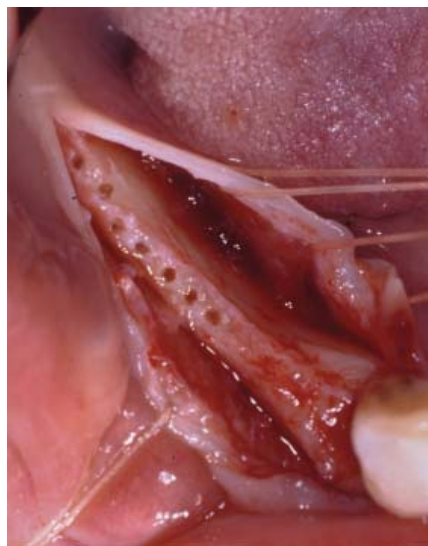


Figure 3: After reflection of the full thickness flaps, a series of small holes were drilled in the alveolar ridge in the right lower molar area.

of the implant site should be consistent with the size of the selected blade, based on the patient's morphological conditions.

In the case of the D3 or D4 bone, the implant site was slightly underprepared, in order to increase immediate stability. Multi-blade drills (009L and 700XXL) mounted on a high-speed handpiece were used to create the implant site. The clinicians prepared the holes with slow movements of the wrist, following the ridge anatomy. Depth of the implant site should not exceed the minimum safety distance from important neighbouring anatomical structures.

After creation of the osteotomy and before implant insertion, it is advisable to check the depth of the site using a probe with 1-mm scaling marks. Implant placement was performed with a pair of pliers, while depth insertion was achieved by light percussion on the implant shoulder using a suitable tool (Figure 5).

Once placement has been completed, the implant shoulder was located below the alveolar ridge to create favourable conditions for proper healing (Figure 6) and assure adequate biological width around the abutment neck, which ensures a long lasting seal around the emerging part

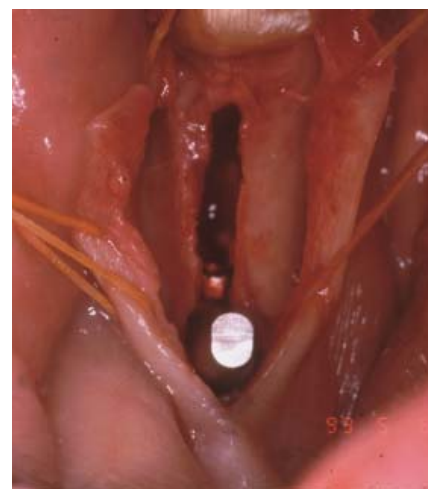


Figure 4: To finish the site and permit insertion of a blade implant, the drilled holes were then connected to each other.

Licensee OA Publishing London 2013. Creative Commons Attribution Licence (CC-BY)

FOR CITATION PURPOSES: Dal Carlo L, Linkow LI, Pasqualini ME, Shulman M, Grivet Brancot L, Nardone M. Blade implants in the rehabilitation of severely atrophic ridges. *Annals of Oral & Maxillofacial Surgery* 2013 Dec 08;1(4):33.

of the implants, that you can check by periodical x-rays.

When the abutment was not aligned with the antagonist tooth, it was bent up to 20° before insertion in order to achieve a more favourable position. Sutures were placed so they surround the emerging abutment in respect to the morphology of

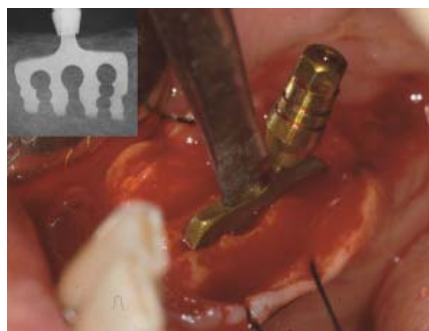

Figure 5: Blade implant during press-fit (lower right molar area).

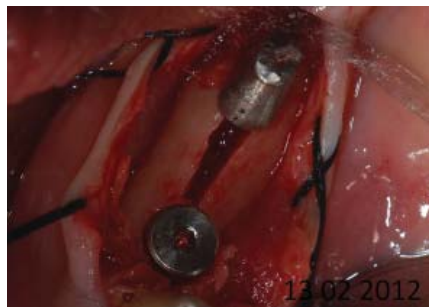

Figure 6: Suture of the surgical opening and around the abutment, which is also surrounded by an adequate band of attached gingiva. A screw implant was placed in the lower right premolar area.

the papillae (Figure 7). The emerging portion of the implant abutment was shielded from any trauma from the teeth, prosthetic structures and soft tissues. Blade implants were immediately loaded when there was a satisfactory primary stability (Table 1).

The static and dynamic occlusal check was performed both during the temporary prosthetic phase and after placement of the final prosthesis. In normal conditions, we recommend a 1:1 clinical crown/clinical root ratio, while, in the case of reduced ridge height, a clinical crown/root ratio > 1:1 is advisable (Figure 8).

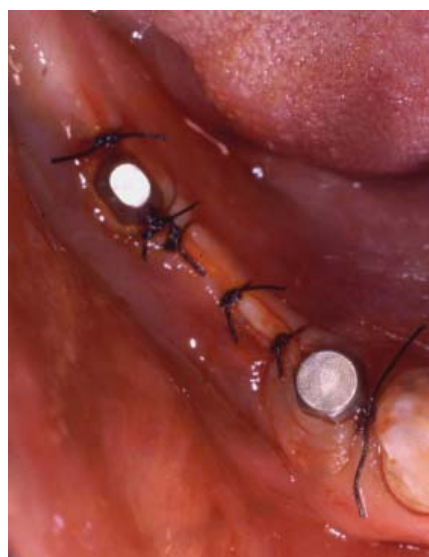

Figure 7: Suture of the surgical opening and around the abutment, which is also surrounded by an adequate band of attached gingiva. A screw implant was placed in the lower right premolar area.

Table 1 Blade implants surgical steps

1. Incision of the alveolar ridge gum;
2. Reflection of a full thickness flap;
3. Marking of the implant site by drilling a small hole in the alveolar ridge;
4. Osteotomy;
5. Measurement of the osteotomy;
6. Shape modification (if needed);
7. Refinishing of the implant site;
8. Adjustment of the abutment with respect to the antagonist tooth;
9. Implant insertion;
10. Suture of the flap.

Methodology

The definitive prosthesis (Figure 9) should not have a cantilever extension, to avoid the risk of implant neck fracture or peri-implantitis due to occlusal trauma. For the treatment of lower posterior sectors in the presence of low-density bone, we used variations of the original technique like the technique named 'endosseous distal extension' (Figure 10). This technique devised in 1993 and

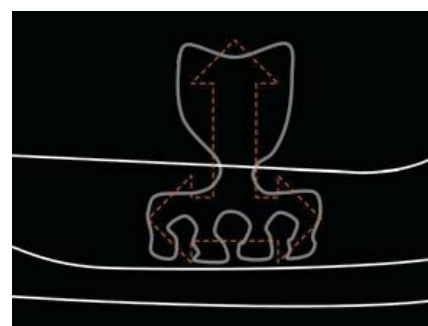


Figure 8: Diagram of a case where the crown/root ratio is at the lower acceptable limits of 1:1.

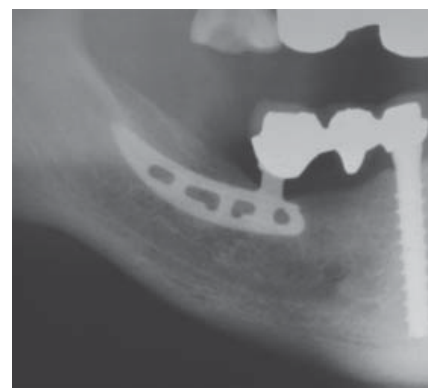

Figure 9: X-ray of the final prosthetic work on implants.

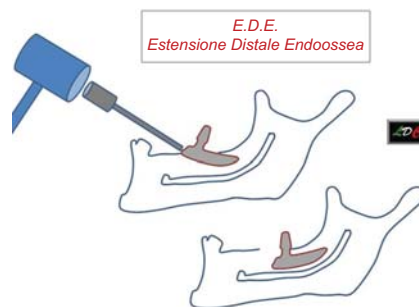

Figure 10: Schematic diagram of the EDE technique.

Licensee OA Publishing London 2013. Creative Commons Attribution Licence (CC-BY)

FOR CITATION PURPOSES: Dal Carlo L, Linkow LI, Pasqualini ME, Shulman M, Grivet Brancot L, Nardone M. Blade implants in the rehabilitation of severely atrophic ridges. Annals of Oral & Maxillofacial Surgery 2013 Dec 08;1(4):33.

divulged in 2001^{12,13} entails the use of the ramus blade implants designed by L.I.L and Ralph Roberts (Figure 11).

The osteotomy is prepared mesially to the final implant site and the blade is rotated and pushed distally, until the abutment reaches the distal end of the implant site (Figure 12). This way, the implant will be almost completely buried. The x-ray shows the presence of intact bone distally to the abutment (Figure 13).

Since the blade is surrounded by healthy soft tissue (Figure 14) and



Figure 11: Ramus blade implant currently on the market.

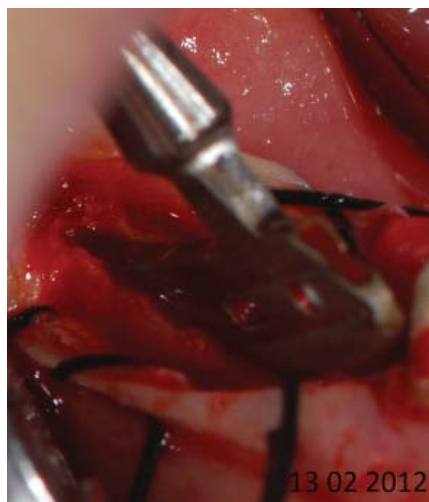

Figure 12: Blade entering the surgical opening created in the lower left premolar region.

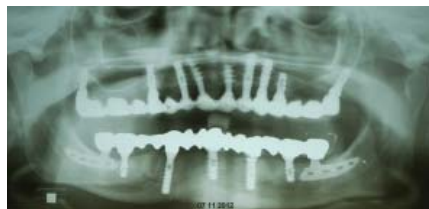

Figure 13: X ray shows intact bone distally to the abutment.

bone in addition to the blade size, there is optimal implant stability, which permits immediate loading. Additional documentation regarding this case is reported in Figures 15–18.

The global success rate was 94% (569/605); 98.8% of the implants (427/432) passed the 5 years,

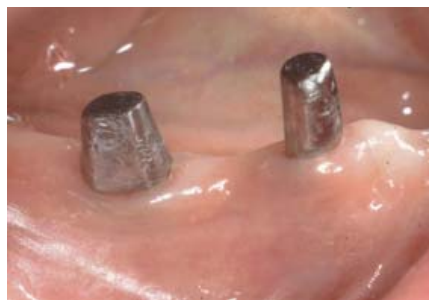

Figure 14: Morphology of the soft tissue surrounding the implant.

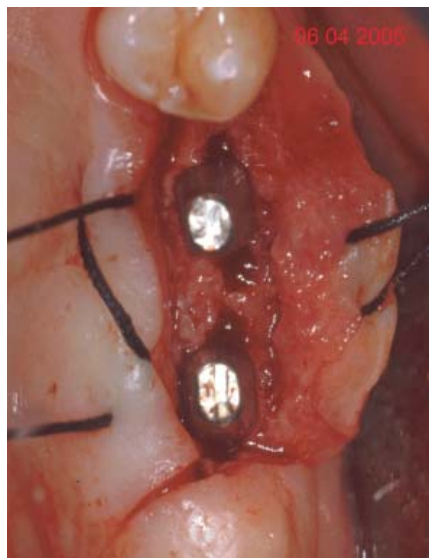


Figure 15: Two blade implants inserted in the upper left area.

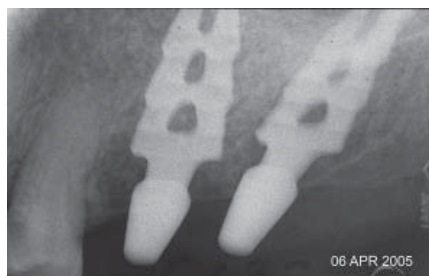

Figure 16: X-ray taken immediately after inserting the two blade implants of Figure 15.

90% (299/332) 8 years and 88.1% (261/296) 10 years.

According to some Authors^{14–17} one of the most frequent and under-investigated causes of implant failure as well as failure of bone grafts in atrophic mandibles may be related to topical vascular rearrangement, a condition that can be particularly severe in adult and elderly patients.

A more detailed analysis¹⁸ was conducted over a 5-year period (June 2000 to June 2005) on blade implants that underwent immediate loading, placed in the posterior sectors (in the area corresponding to the first and

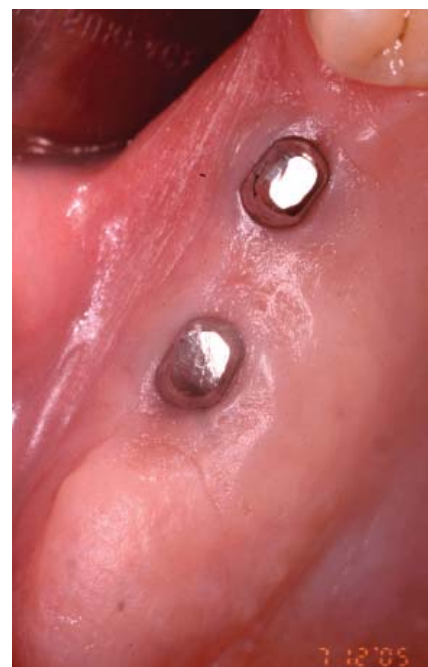

Figure 17: Image of the optimal healing of the soft tissue surrounding the two blade implants of Figure 15.

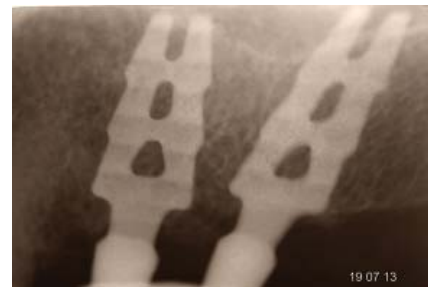


Figure 18: X-ray taken 8 years after intervention the two blade implants of Figure 15.

Licensee OA Publishing London 2013. Creative Commons Attribution Licence (CC-BY)

FOR CITATION PURPOSES: Dal Carlo L, Linkow LI, Pasqualini ME, Shulman M, Grivet Brancot L, Nardone M. Blade implants in the rehabilitation of severely atrophic ridges. *Annals of Oral & Maxillofacial Surgery* 2013 Dec 08;1(4):33.

second lower molars), in addition to a single-phase implant placed anteriorly to the mental foramen (total 54 implants). Two implants were immediately splinted with a soldered titanium bar and loaded with a fixed temporary prosthesis.

The same approach was employed in 27 mandibles, placing 27 implants of each type (for a total of 54 implants). In a patient with osteoporosis, the implant caused pain upon percussion; therefore, it was stabilised with a needle implant soldered to the blade. In two cases, the screw implants had to be replaced with implants with a larger diameter, which were then immediately loaded. The data presented in this study were as follows at the 2008 follow-up:

- 100% success rate for blade implants placed in the mandible and immediately loaded, or 96.2% success rate^{19,20} if the blade implant stabilised with a needle was classified as a failure.
- 93.1% success rate^{20,21} for the single-phase implants immediately loaded and laced in the second lower pre-molar area.

Similar results were obtained in another study by U. Pasqualini et al.⁴, who reported a success rate of 91% at 10 years for 386 blade implants placed between 1971 and 2009. The effectiveness of blade implants was documented in a 5-year multi-centric randomised study conducted by an independent group²². This study reported a 91.5% success rate for cases of partial edentulism treated with fixed dental prostheses on blade implants.

Discussion

L.I.L.'s introduction of blade implants in the 1960s was ground-breaking and convinced many neophyte implantologists to employ them, without fully understanding their indications or the proper post-operative management procedures.

Poor knowledge and improper use of this surgical-prosthetic device are the main reasons for their subsequent failure. Other studies underscored the advantages of the blades after failure of conventional root-form implants²³.

By comparing different implants placed in the same period, Knöfler et al. assessed the long-term reliability of blade implants^{19,24}. Other studies²⁰ contradict criticism on the impossibility of replacing a blade implant that failed to osseointegrate with a similar one. The long-term success of blade implants has been demonstrated by several clinical studies, and the literature shows that blade implants have a 41-year documented follow-up^{21,25}. Their osseointegration has been demonstrated by many histology papers^{23,26} and recently confirmed by a study conducted in 2011¹⁸.

In a study published in 2012, Iezzi et al.¹⁰ reported the results of a histology and istomorphometric analysis on 31 blade implants explanted after 2 to 23 years of loading, demonstrating that all of them were surrounded by mineralised tissues.

In 2012, Mangano et al.²⁷ proposed the customised selective laser sintering of implants for treatment of the posterior sectors of atrophic mandibles. Criticism of the lack of osseointegration which would be a common outcome with this technique, has invariably been proved wrong by authoritative histology studies^{9,23}.

Conclusion

The blade implant is an effective therapeutic device that is useful in the implant and prosthetic rehabilitation of severely atrophic ridges with a reduced trabecular component in the lower posterior sectors. In addition, its placement does not require a previous or concomitant grafting procedure, thus lowering the economic and biological costs. After proper training, implant placement is simple and morbidity is close to negligible, making the use of blade implants a very versatile method.

The distally extended type can be employed in the posterior sectors, both upper and lower, while in the front aesthetic area and in the lateral sectors, the blade can be used when an alternative device would entail less predictable and more invasive procedures. The response of the soft tissues surrounding this type of implant is excellent.

Based on the data available in the literature, blade implants are not specifically indicated only for ridges of poorly mineralised and scarcely retentive D4 bone.

Acknowledgements

Images offered by L.D.C. and M.E.P.

References

1. Linkow LI. The blade vent - a new dimension in endosseous implantology. *Dent Concepts*. 1968;11:3-12.
2. Linkow LI. The endosseous blade: a new dimension in oral implantology. *Rev Trim Implant*. 1968;5:13-24.
3. Linkow LI. Endosseous bladevent implant-insertion guidelines. *Dentistry Today*. 1984 Jun;III(6).
4. Pasqualini U, Pasqualini ME. *Treatise of implant dentistry*. AriesDue srl Carimate Como. 2009.
5. Babbush CA. Endosteal bladevent implants. *Dent Clin North Am*. 1986;30:97-115.
6. Pasqualini U. Impianti Endosseoi: La protezione dell'osteogenesi riparativa con la metodica del "moncone avvitato". *Tecnica personale*. Dental Cadmos 1972;8:3-13.
7. Roberts RA. Types, uses, and evaluation of the plate-form implant. *J Oral Implantol*. 1996;22:111-8.
8. Muratori G. Blade implants simplified. *Attual Dent*. 1986 Apr;2:44-5.
9. Di Stefano D, Iezzi G, Scarano A, Perrotti V, Piattelli A. Immediately loaded blade implant retrieved from a after a 20-year loading period: a histologic and histomorphometric case report. *J Oral Implantol*. 2006;32:171-6.
10. Iezzi G, Scarano A, Perrotti V, Tripodi D, Piattelli A. Impianti a lama a carico immediato. Analisi istologica e istomorfometrica dopo un lungo periodo di carico. Analisi retrospettiva a 20 anni (1989 - 2009). *J. Osseointegration*. 2012;3:99-104.

Licensee OA Publishing London 2013. Creative Commons Attribution Licence (CC-BY)

FOR CITATION PURPOSES: Dal Carlo L, Linkow LI, Pasqualini ME, Shulman M, Grivet Brancot L, Nardone M. Blade implants in the rehabilitation of severely atrophic ridges. *Annals of Oral & Maxillofacial Surgery* 2013 Dec 08;1(4):33.

Methodology

11. Dal Carlo L, Pasqualini ME, Carinci F, Corradini M, Vannini F, Nardone M, et al. A brief history and guidelines of blade implant technique: a retrospective study on 522 implants. *Annals of Oral & Maxillofacial Surgery*. 2013;1:1–4.
12. Dal Carlo L. Nuova tecnica per l'inserzione di impianti a lama: Estensione Distale Endosseosa. *Dental Cadmos*. 2001;16:41–49.
13. Dal Carlo L. Endosseous distal extension: a new technique that is useful to solve clinical cases characterized by scarceness of cancellous bone tissue in the lower distal sector. *Stomatologhieski J*. 2002;3:30–34.
14. Bradley JC. Age changes in the vascular supply of the mandible. *Br Dent J*. 1972;132:142–4.
15. Bradley JC. A radiological investigation into the age changes of the inferior dental artery. *Br Oral Surg*. 1975 Jul;13:82–90.
16. Hellem S, Ostrup LT. Normal and retrograde blood supply to the body of the mandible in the dog. II. The role played by periosteal-medullary and symphyseal anastomoses. *Int J Oral Surg*. 1981 Feb;10:31–42.
17. Castelli WA, Nasjleti CE, Diaz-Perez R. Interruption of the arterial inferior alveolar flow and its effects on mandibular collateral circulation and dental tissues. *J Dent Res*. 1975 Jul-Aug;54:708–15.
18. Dal Carlo L. Studio Statistico su 6200 impianti inseriti in 20 anni in 2800 interventi. *Odontoline*. 2011.
19. Strecha J, Jurkovic R, Siebert T, Prachar P, Bartakova S. Fixed bicortical screw and blade implants as a non-standard solution to an edentulous (toothless) mandible. *Int J Oral Sci*. 2010;2:105–10.
20. Covani U, Marconcini S, Crespi R, Barone A. Immediate implant placement after removal of a failed implant: a clinical and histological case report. *J Oral Implantol*. 2009;35:189–95.
21. Pasqualini ME. Implantoprotesi in un caso di monoedentulismo. *Analisi retrospettiva a 38 anni*. *Dental Cadmos* 2010;10:65–70.
22. Garrett NR, Kapur KK, Hasse AL, Dent RJ. Veterans Administration Cooperative Dental Implant Study - comparisons between fixed partial dentures supported by blade-vent implants and removable partial dentures. Part V: Comparisons of pretreatment and post-treatment dietary intakes. *J Prosthet Dent*. 1997;77:153–61.
23. Linkow LI, Donath K, Lemons JE. Retrieval analyses of a blade implant after 231 months of clinical function. *Implant Dent*. 1992;1:37–43.
24. Knöfler W, Knöfler A, Graf HL. Survival analysis of implants in a dental office over a period of 10 years. *Zeitschrift für Zahnärztliche Implantologie* 2004;20.
25. Koch WL. Statistical evaluation of success and reasons for failure in 700 endosseous blade implants done in the office. *Orale Implantol*. 1974 Apr;1:105–38.
26. Trisi P, Quaranta M, Emanuelli M, Piattelli A. A light microscopy, scanning electron microscopy, and laser scanning microscopy analysis of retrieved blade implants after 7 to 20 years of clinical function. A report of 3 cases. *J Periodontol*. 1993 May;64:374–8.
27. Mangano F, Bazzoli M, Tettamanti L, Farronato D, Maineri M, Macchi A, et al. Custom-made, selective laser sintering (SLS) blade implants as a non-conventional solution for the prosthetic rehabilitation of extremely atrophied posterior mandible. *Lasers Med Sci*. 2013 Sep;28:1241–7.