

Syncrystallization: A Technique for Temporization of Immediately Loaded Implants with Metal-Reinforced Acrylic Resin Restorations

Marco Degidi, MD, DDS;* Peter Gehrke, DDS;† Andre Spanel, Dipl. Ing.;‡ Adriano Piattelli, MD, DDS§

ABSTRACT

Background: Rigid temporization has been recognized to have a significant impact on the peri-implant tissue response in immediate implant loading since it reduces the mechanical stress exerted on each implant.

Purpose: A successful protocol for immediate loading of multiple implants depends on an adequate fixation and immobility of the implants to prevent the risk of micromovements in relation to the surrounding bone. The objective of this article was to evaluate a prosthetic concept for an accelerated rigid splinting of multiple implants for same-day immediate loading with metal-reinforced provisional restorations using a technique of welding temporary implant abutments with a prefabricated titanium bar directly in the oral cavity (syncrystallization).

Materials and Methods: Between June 2004 and January 2005, immediate loading of threaded implants with a metal-reinforced acrylic resin provisional restoration at stage 1 surgery was evaluated in 40 consecutive patients. A total of 192 implants were placed in selected edentulous or partially edentulous patients using the syncrystallization technique. Once the titanium bar was welded intraorally to the abutments, opaque was applied and the provisional restoration was relined and screw-retained the same day. In addition, a comparison of deformations and stress distributions in implant-supported, metal-reinforced and nonmetal-reinforced resin provisional restorations was analyzed in the edentulous mandible by a three-dimensional finite element model (FEM).

Results: All of the 192 rigidly temporized immediately loaded implants osseointegrated. An implant success rate of 100% was achieved over a period of 6 months postplacement. No fracture or luting cement failure of the provisional restoration occurred during the observation time. Compared to mere acrylic superstructures, a significant reduction of deformation and strain within metal-reinforced provisional restorations was detected by FEM analysis.

Conclusion: The results of this study indicate that the syncrystallization technique allows an expedite and adequate rigid splinting of multiple immediately loaded implants. The advantages of the technique are: (1) reduction of treatment time for immediate temporization at stage 1 surgery; (2) predictable fixation and immobility of implants in the early stages of bone healing; and (3) less time for repairing provisional restorations as a result of no or rare fracture.

KEY WORDS: finite element model, immediate loading, metal-reinforced provisional restorations, syncrystallization

Although initial considerations in implant dentistry have claimed that the process of osseointegration requires on average an undisturbed healing of 3 months in the mandible and 6 months in the maxilla,¹⁻³ an

*Private practice, Bologna, Italy, and visiting professor, University of Chieti, Pescara, Italy; †private practice, Ludwigshafen, Germany; ‡DENTSPLY Friadent, Mannheim, Germany; §professor of oral pathology and medicine, Dental School, University of Chieti, Pescara, Italy

Reprint requests: Professor Adriano Piattelli, Via F. Sciucchi 63, 66100 Chieti, Italy; e-mail: apiattelli@unich.it

© 2006 Blackwell Publishing, Inc.

DOI 10.1111/j.1708-8208.2006.00011.x

increasing interest has been noticed with regard to early and immediate loading of implants to expedite the restorative outcome. Donath and colleagues⁴ reported that load exerted at the implant interface may interfere with the process of bone healing and lead to fibrous encapsulation. However, clinical and experimental animal trials have shown that long-term success of removable and fixed prostheses of immediately loaded dental implants can be achieved.⁵⁻²¹ In a clinical study involving the analysis of a substantial number of implants, the authors demonstrated the predictability and high success rates of immediate functional and non-functional loading.²² Recently published results of a 7-

year follow up of immediately loaded implants revealed comparable outcomes for delayed loaded implants with a satisfactory level of osseointegration and high success rates.²³ In addition, initial implant mobility does not inevitably prevent osseointegration.²⁴ In general, micromotion at the implant interface has to be distinguished from uncontrolled masticatory forces. The peri-implant bone adjusts its architecture according to its capacity to withstand functional loading. Consequently, the strains induced by these loads affect the bone remodeling process. It has been suggested in the literature that the magnitude of the load forces between the implant and the bone determines the implant success.²⁵ Therefore, one key to the success of titanium implants seems to be the adequate bone remodeling at the periphery of the implant.²⁶ Microstrain may be a favorable stimulus during the healing period of implants resulting in an increased bone density.²⁷⁻³³ According to Brunski and colleagues,³⁴⁻³⁷ implants can be loaded early or immediately, if micromovements above a threshold of 100 μm can be avoided during the healing phase. Stronger movements would lead to soft tissue ingrowth at the interface rather than to the desired bone apposition. Cameron and colleagues³⁸ reported that osseointegration can be achieved even with micromovements, but not with so-called macromovements. In spite of the lack of a consistent terminology on the definition of micro- and macromovements, it has been suggested that a movement of 30 μm or less has no adverse effect on integration, while a movement of 150 μm or more results in soft connective tissue apposition to the implant.³⁹⁻⁴¹ In this context, it can no longer be assumed that immediate loading per se leads to the fibrous encapsulation of implants.⁴² A successful, accelerated protocol for implant rehabilitation depends upon several interactive factors: besides accurate presurgical diagnostics and treatment planning, implant macro- and microdesign, the adequate fixation and immobility of the implant are of utmost importance to prevent the risk of micromovements related to the surrounding bone. Rigid splinting seems to have a significant impact on the peri-implant tissue response since it is able to reduce the mechanical stress exerted on each implant. If rigidity is lost, implant failure is likely to occur due to uncontrolled masticatory forces. Consequently, the stability of the prosthetic restoration and the ability to keep the micromovements below the critical threshold are considerably increased by rigid splinting. Prosthetic con-

cepts for immediate loading of multiple implants in the edentulous or partially edentulous mandible and maxilla reported in the literature involve bar-supported overdentures in the mandible,^{8,9} retrofitting of preexisting prostheses to implants,⁴³⁻⁴⁵ or fabricating acrylic resin provisional restorations.^{10,13} A high predictability of immediate implant loading with fixed provisional restorations has been shown in several reports.^{16,17,46} This indicates that rigid acrylic resin provisional restorations are able to confine the occlusal forces applied to the bone-implant interface to a physiological range. Material stability and fracture strength are essential in maintaining the rigidity of provisional restorations on immediately loaded implants over a longer period of time. However, long-span acrylic resin restorations are subject to flexion and fracture under occlusal forces. This applies in particular for a cross-arch stabilization of multiple implants in the edentulous mandible. The human mandible presents a complex elastic biomechanical behavior under functional loading. This is a result both of its U-shaped anatomic conformation with posterior insertion sites of masticatory muscles, and of the complex structure and elasticity of the constituent bone.⁴⁷ It is known that the simultaneous contraction of the lateral pterygoid muscles during mandibular opening and protrusion exerts a medial, forward, and downward traction of the condyles.⁴⁸ As a consequence of the elastic flexure of the mandible, the distance between the left and the right mandibular ramous on the frontal plane is reduced. The flexure has been assumed to take place around the symphysis generating a reduction of width in the posterior regions of the mandible. From a biomechanical point of view, a rigid splint of dental implants by means of a fixed cross-arch bridge could induce torsional stress that could be transmitted to the prosthetic superstructure, leading to fracture of the restoration and failure of the luting cement. Previously described techniques for reinforcement of acrylic resin provisional restorations involve either the use of a thin wire or fibers throughout the span, or a time-consuming fabrication of a cast metal framework in the laboratory that covers the facial and/or lingual surfaces of the provisional restoration.^{26,49-53} While Longoni and colleagues⁵⁴ reported a method to reduce prosthetic misfit of implant-supported complete dentures using the combination of intraoral luting and extraoral laser welding, Hruska⁵⁵ and Mondani and Mondani⁵⁶ introduced a time-effective intraoral welding

technique of titanium components for different dental and implant restorations to avoid long laboratory procedures. The objective of this article was to evaluate a prosthetic concept for an accelerated rigid splinting of multiple implants for same-day immediate loading with metal-reinforced acrylic resin provisional restorations by a technique of welding temporary implant abutments with a prefabricated titanium bar directly in the oral cavity. In addition, a comparison of the biomechanical effect of bite forces and mandibular functional flexure on stress buildup in temporary implant-supported fixed restorations is discussed. The relative deformations and stress distributions in metal-reinforced and nonmetal-reinforced acrylic resin provisional restorations in the edentulous mandible were analyzed by a three-dimensional finite element model (FEM).

MATERIALS AND METHODS

Patient Criteria

Forty patients were treated between June 2004 and January 2005. The subjects were screened according to the following inclusion criteria: a recipient bone site that allowed the insertion of an implant with a minimum length of 10 mm and a minimum diameter of 3.5 mm, no need of bone augmentation procedures prior to implant placement, controlled oral hygiene, no tooth decay in cases of partial edentulism and no active periodontal disease, and the willingness of the patient to give informed consent. The exclusion criteria were as follows: nontreated caries and uncontrolled periodontal disease in cases of partial edentulism, adjacent teeth that exceeded class I mobility, bruxism or other parafunctional habits, unstable posterior occlusion (missing or early contacts in maximum intercuspation), smoking more than 20 cigarettes per day, and general health or medications that might compromise the osseointegration process (Figure 1).

Surgical Procedure

All patients underwent the same surgical protocol. Antimicrobial prophylaxis was obtained with amoxicillin 500 mg twice daily for 5 days starting 1 hour before surgery. Local anesthesia was induced by infiltration with articaine/epinephrine and postsurgical analgesic treatment was performed with Nimesulide™ (Merck Generics Italy, Milano, Italy) 100 mg twice daily for 3 days. The patients had a soft diet for 4 weeks. Oral

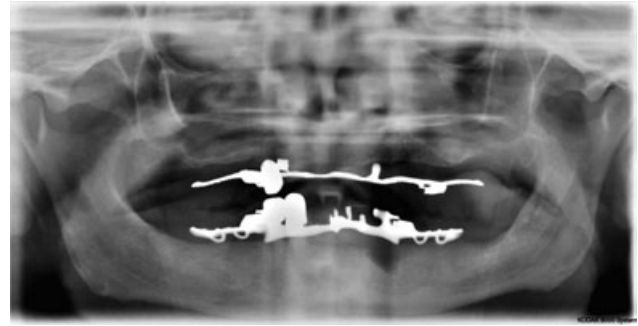


Figure 1 Preoperative orthopantomograph x-ray.

hygiene instructions were provided. A mucoperiosteal flap was elevated after crestal incision. Implants were placed following the respective manufacturers' instructions. A minimum insertion torque of 30 Ncm was used for all implants that were clinically stable. A total of 192 implants were inserted: 16 FRIALIT®, 112 XiVE®, 13 XiVE TG®, and 23 ANKYLOS® (DENTSPLY Friadent, Mannheim, Germany); and 14 Maestro® and 14 Prodigy® (Biohorizons, Birmingham, AL, USA). Twenty-six partially edentulous patients received 89 implants in the following sites: two central incisors, four lateral incisors, 10 cuspids, 40 premolars, and 33 molars. Forty-two implants were placed in the edentulous maxilla of six patients, and 61 implants in the edentulous mandible of eight patients. The distribution of implant location and type is summarized in Table 1, A–F.

TABLE 1 A, Number of Implants and Cases According to Partial and Total Edentulism		
	Number of Cases	Number of Implants
Totally edentulous	14	103
Partially edentulous	26	89
Total	40	192

TABLE 1 B, Number of Implants and Cases of Edentulous Patients		
	Number of Cases	Number of Implants
Edentulous mandible	8	61
Edentulous maxilla	6	42
Total	14	103

TABLE 1 C, Number of Implants and Cases of Partially Edentulous Patients		
	Number of Cases	Number of Implants
Posterior mandible	13	42
Posterior maxilla	9	33
Anterior mandible	—	—
Anterior maxilla	4	14
Total	26	89

TABLE 1 D, Maxillary Implant Site in Partially Edentulous Patients	
Implant Site Maxilla	<i>n</i>
Central incisor	2
Lateral incisor	4
Cuspid	8
Premolar	20
Molar	13
Total	47

TABLE 1 E, Mandibular Implant Site in Partially Edentulous Patients	
Implant Region Mandibula	<i>n</i>
Central incisor	—
Lateral incisor	—
Cuspid	2
Premolar	20
Molar	20
Total	42

TABLE 1 F, Number of Implant Types Inserted	
Implant	<i>n</i>
Frialit	16
XiVE	112
XiVE TG	13
Maestro	14
Prodigy	14
Ankylos	23
Total	192

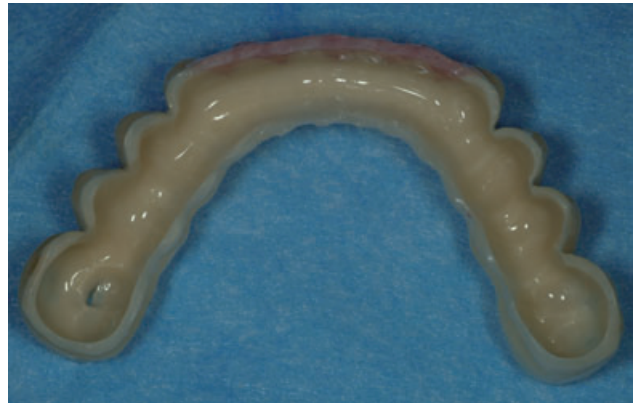

Figure 2 Hollow acrylic resin provisional restoration prior to relining.

Syncrystallization and Laboratory Procedure

First, a facebow transfer and a centric relation record were utilized to mount the diagnostic casts on a semi-adjustable articulator. Subsequently, a diagnostic wax-up for a preliminary provisional fixed restoration was fabricated and converted to autopolymerizing resin (Figure 2). After surgical placement of the implants, temporary titanium abutments were connected to them (Figure 3). If implants with an internal hexagon were used, the connection was rounded before the welding process, avoiding a nonretrievability of the welded piece in case of pronounced disparallelism. The abutments used consisted of two parts (abutment and retaining screw) in order to ensure the retrievability of the welded piece. A preexisting or prepared flat surface area served as the welding point. A titanium bar was shaped following the curvature of the implants positioned. At this point, temporary titanium implant abutments were welded with the titanium bar in the oral cavity (Figures 4 and 5), using the Syncrystallization Unit®

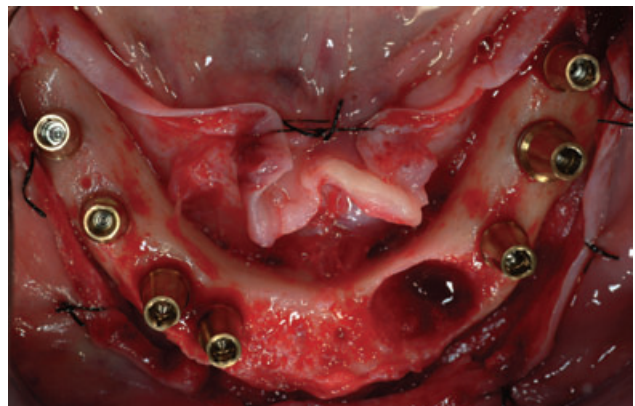


Figure 3 Clinical view after implant placement.




Figure 4 Occlusal view of intraoral welding process: Welding clamps holding implant abutment and titanium bar.

(System Argon Control, IMPLAMED, Cremona, Italy). The welding process is electrical and protected by an argon gas supply (Syncrystallization). The equipment allows the welding of metallic elements directly in the mouth. The two elements to be welded are placed between the two electrodes of a welding clamp. The energy contained in a previously unloaded battery of capacitors is transferred to the electrodes of the welding clamp. Current flowing through the contact points, being in contact with the parts to weld, warms up to the point of fusion, achieving a solid, welded junction (Figure 6). The welding cycle is subdivided in three stages: Pre-gas, welding, and post-gas phase. While the pre-gas phase allows an oxygen-free welding point prior to the actual fusion, the post-gas phase ensures the absence of oxygen and subsequent oxidation during cooling. A barely perceptible sound can be perceived during the use of the Syncrystallization Unit. Welding of the pieces takes only a fraction of a second. The process

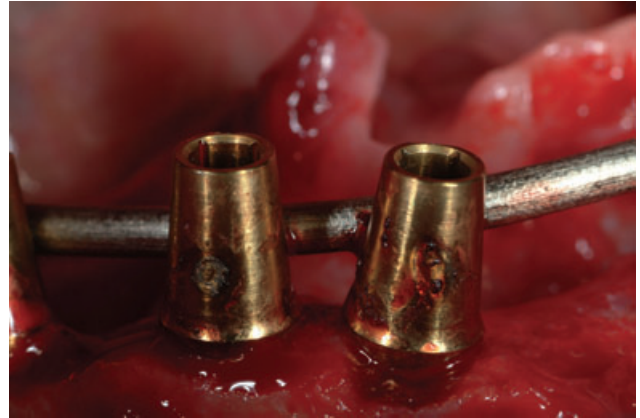


Figure 6 Close-up of welding spot.

is carried out without producing any heat, causing no discomfort to the patient or damage to surrounding tissues. The quality of the welding joint between the two titanium components is very good either at low or high magnification (Figures 11 and 12). Finally, the prosthetic framework, created by welding the titanium bar to the implant abutments, was removed and opaque was applied in order to avoid metal shining through the acrylic resin. The provisional restoration was relined, trimmed, polished, and screw-retained the same day (Figures 7–10). Occlusal contact was avoided in centric and lateral excursions.

Finite Element Analysis

A mandibular three-dimensional FEM was created by sequential sectioning, scanning, and imaging of a solid-foam edentulous mandible (Sawbones®, Pacific Research Laboratories, Inc., Malmö, Sweden). The mandibular section profiles were collected at 8-mm increments. The intercondylar dimension was 8 mm.

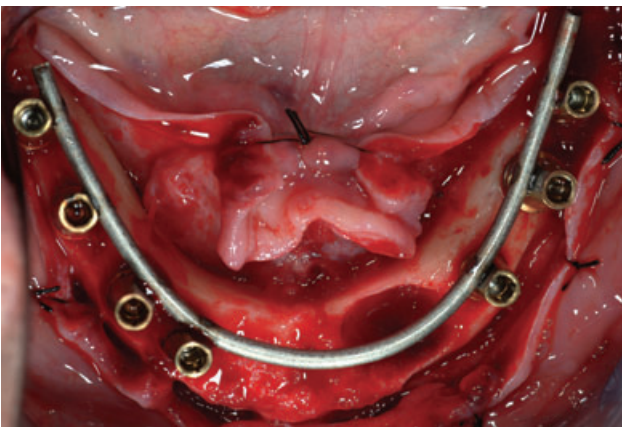


Figure 5 Intraorally welded titanium bar.

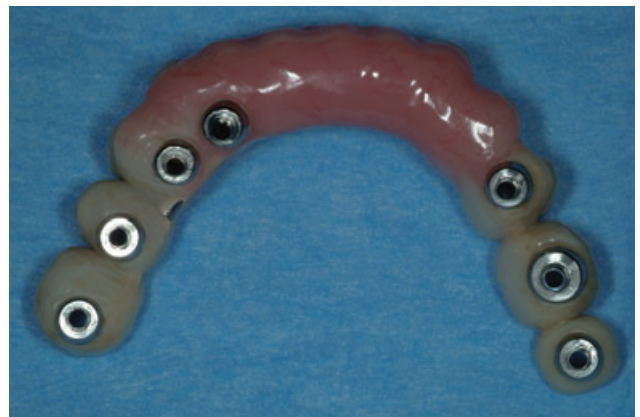

Figure 7 Provisional metal-reinforced restoration after relining, trimming, and polishing ready to be delivered 2 hours later.

Figure 8 Occlusal view of screw-retained mandibular metal-reinforced provisional restoration in situ.

The height of the mandibular bone in the symphysis was 30 and 18 mm in the left, respectively, and 15 mm in the right first molar region. All traces were assembled into a three-dimensional wire frame model by means of an ordinary three-dimensional computer-aided design. Four threaded cylindrical titanium implants (XiVE, DENTSPLY Friadent) with a total length of 13 mm and a diameter of 3.8 mm were incorporated into the model. Each implant was fully inserted into the bone, and temporary titanium abutments (TempBase, DENTSPLY Friadent) were mounted. Two implants were placed in each quadrant of the mandible in the center of the mandibular crest, symmetrically to the midsagittal plane, within the region of the canine and second premolar. Three-dimensional mandibular models of an implant-supported, cross-arch provisional restoration on four implants with and without metal reinforcement (Figures 13 and 14) were analyzed and compared. Both prosthetic superstructures were conceived as fixed, acrylic

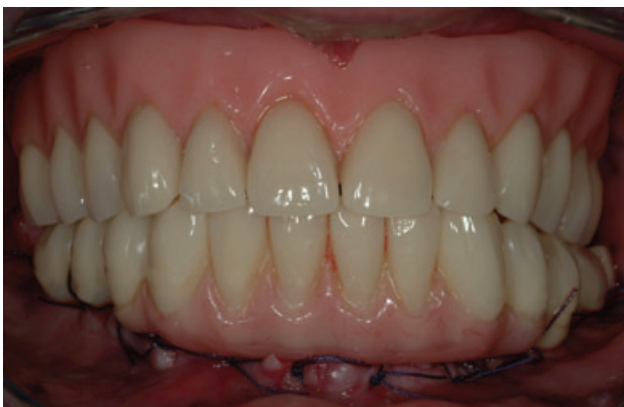

Figure 9 Labial view of maxillary prosthesis and mandibular provisional restoration.

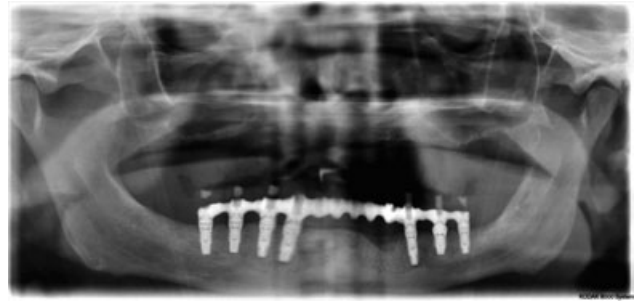


Figure 10 Immediate postoperative orthopantomograph x-ray.




Figure 11 Cross section of a welding joint at 20-fold magnification. Temporary abutment (round section above) and titanium bar (straight section below).




Figure 12 Welding joint at 50,000-fold magnification. Only minor porosity can be detected.

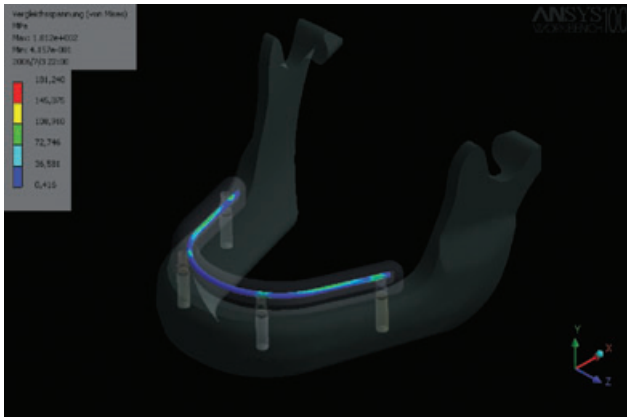


Figure 13 Finite element mandibular model of implant-supported, cross-arch provisional restoration on four implants *with* incorporated titanium bar reinforcement.

resin, symmetrical bridges with a section of 7×9 mm. One model was additionally reinforced by a metal framework fabricated of titanium implant abutments, intraorally welded to a titanium bar of 2 mm in diameter. In accordance to FEM accuracy requirements of using a model over 30,000 degrees of freedom,^{57–59} the final FEM model was designed linearly, using 90,000 solid elements. The specific element types used in the analysis are listed in Table 2. Subsequently, a virtual masticatory load was chosen according to clinical conditions in the oral cavity. Apart from individual anatomic and physiologic characteristics, previous studies have shown that maximal bite forces vary according to the region in the oral cavity.^{60–63} While the greatest bite force was found in the first molar region, incisors only bear about one-third to one-fourth of that force in the posterior region. Mean values varying from 180 to 847 N for the maximum force level could be shown, whereas smaller values ranging from 94 to 250 N have been reported for the incisal region. Consequently, masticatory forces in the present FEM were simulated using average external loads of 300 N in the anterior region (incisors to canines), and 900 N in the posterior region (premolars




Figure 14 Finite element mandibular model of implant-supported, cross-arch acrylic provisional restoration on four implants *without* metal reinforcement.

to molars). FEM was carried out by Ansys® 8.0 software (ANSYS Inc., Canonsburg, PA, USA) comparing von-der-Mises and maximum stress levels obtained from the calculation. The following assumptions were made to simulate the mechanical behavior of mandibular bone:

1. Total bonding between bone and implants (complete implant osseointegration).
2. Considering an atrophied edentulous mandible, bony tissue was simulated by assuming solely cortical bone with a Young’s modulus of 13.7 GPa. A Young’s modulus of 115 GPa was assumed for the titanium implant (grade 2). The choice of the applied Young’s modulus for cortical bone and titanium was within the range of values reported in the literature.^{47,64–66} Literature references and reported physical properties are itemized in Table 3. A Young’s modulus of 96 GPa was assumed for the implant abutment (titanium alloy)⁶⁷ and 3.2 GPa for the autopolymerizing polymethyl-methacrylate.⁶⁸

TABLE 2 Overview of Elements used in Finite Element Model

Name of Element Type	ANSYS – Name	Description
10-Node quadratic tetrahedron	Solid187	10-Node tetrahedral structural solid
20-Node quadratic hexahedron	Solid186	20-Node hexahedral structural solid
6-Node quadratic triangular contact	Conta174	Hi-order surface-surface contact
6-Node quadratic triangular target	Targe170	Surface contact target
8-Node quadratic quadrilateral contact	Conta174	Hi-order surface-surface contact
8-Node quadratic quadrilateral target	Targe170	Surface contact target

TABLE 3 Physical Material Properties of Bone and Titanium with Corresponding References

	Young's Modulus (GPa) – Reference	Young's Modulus (GPa) – Reference	Young's Modulus (GPa) – Reference	Young's Modulus (GPa) – Reference
Cortical bone	13.7–64	13.7–66	14.7–65	15–47
Cancellous bone	2.5–64	1.37–66	0.5–65	1.5–47
Titanium	107–64	110–66	117–65	110–47

3. The cortical bone thickness was considered consistently throughout the mandibular body.
4. An arbitrary load of 10N was applied in the x-direction on the mandible, simulating previously reported forces of the lateral pterygoid muscles pulling medially on the condyles.^{47,48}
5. The structural analysis was assumed linear and static.

RESULTS

All of the 192 rigidly temporized immediately loaded implants osseointegrated. An implant success rate of 100% was achieved over a period of 6 months post-placement. No fracture or luting cement failure of the provisional restoration occurred during the observation time. In comparison to mere acrylic superstructures, a significant reduction of deformation and strain within metal-reinforced acrylic resin provisional restorations could be detected in FEM analysis. The titanium framework-reinforced provisional restorations investigated in the current study exhibited a reduction of maximum von-Mises strain values of 300–500% at external loads of 300N in the anterior and 900N in the posterior region. The strain values measured at the implant abutments and along the provisional spans are

given in Tables 4–6. With regard to the relationship between stress distribution and implant location along the mandibular arch, maximum stress values were located at the level of the most distal implants.

DISCUSSION

An optimal biomechanical stress distribution, both at the level of the provisional superstructure and at the level of the implant infrastructure, is the primary aim of the rigid temporization of multiple immediately loaded implants. Stress distribution in mandibular, fixed, implant-supported restorations is greatly influenced by many variables, including prosthetic design and material, occlusal scheme, bone structure, shape and activity of masticatory muscles, implant location, as well as design and material of implants and implant abutments. Although the present FEM analysis revealed a high decrease of deformation and maximum strain in titanium framework-reinforced acrylic resin restorations, caution must be given when extrapolating FEM data to clinical situations, since multiple in vivo variables are excluded from a controlled computer analysis. The tendency of strain reduction was, however, obvious. Research in fixed implant prosthodontics on osseointegrated implants has advised to section the superstructure in multiple free-standing bridges, rather than designing one cross-arch rigid restoration.^{47,69} A rigid restorative system could not follow the flexure of the mandibular bone, generating high stress concentrations and increasing the rate of screw loosening and fractures. In the treatment concept of immediate implant loading, however, an adequate fixation and immobility of implants in the early stages of bone healing is a prerequisite to prevent micromovements in relation to the surrounding bone. After successful osseointegration of immediately loaded implants, splitting the final superstructure into multiple free-standing bridges should be taken into account, thereby allowing an adequate stress distribution and a better prosthetic fit as a result of fewer

TABLE 4 Strain and Deformation Values for Mere (Nonmetal-Reinforced) Acrylic Resin Provisional Restoration

Object	Maximum (von-Mises) Strain (MPa)	Maximum Deformation (mm)
Acrylic resin restoration	57, 74	0.16
Titanium bar	—	—
TempBase abutment 35	2.591, 51	0.0189
TempBase abutment 33	1.479, 43	0.00747
TempBase abutment 43	1.346, 09	0.00748
TempBase abutment 45	3.775, 88	0.0188

TABLE 5 Strain and Deformation Values for Titanium Framework-Reinforced Acrylic Resin Provisional Restoration and Its Strain Reduction Compared to Nonmetal-Reinforced Provisional Restorations

Object	Maximum (von-Mises) Strain (MPa)	Maximum Deformation (mm)	Strain Reduction (%)
Acrylic resin restoration	103, 74	0.1	+79
Titanium bar	162, 64	0.0991	—
TempBase abutment 35	802, 14	0.02	-323
TempBase abutment 33	453, 27	0.00876	-326
TempBase abutment 43	447, 14	0.00878	-301
TempBase abutment 45	722, 54	0.0184	-525

connected abutments. Prosthodontic challenges in fixed immediate temporization of multiple implants can be both safely and predictably addressed when using the syncrystallization technique. In addition to rigid implant splinting, the provisional restoration serves as a guide for the final superstructure while aesthetics and phonetics are evaluated for patient acceptance. The temporization procedure can be significantly accelerated and causes minimal discomfort or interruption in function and cosmetics for the patient. Although using the Syncrystallization Unit needs no specific training, an excellent collaboration between the restorative-experienced surgeon and the laboratory team is desirable. The equipment is easy to employ and is currently in the process of modification to reduce the size of the welding clamp as well as the weight of the unit. The device can be obtained worldwide and has received consumer electronics certification, meeting the requirements of European Directives for Medical Devices. It has

not been approved by the Food and Drug Administration for the US market yet.

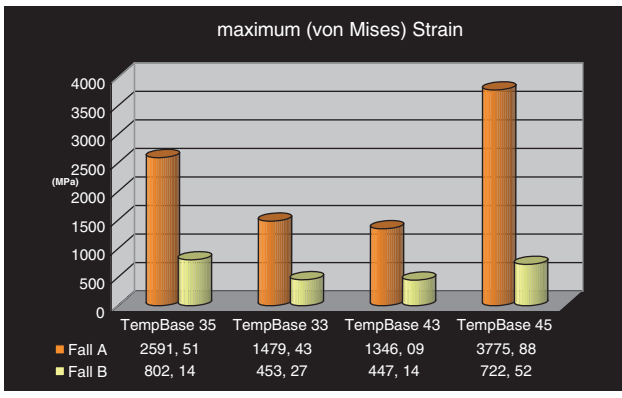
CONCLUSION

The results of this study indicate that the syncrystallization technique allows an expedite and adequate rigid splinting of multiple implants for same-day immediate loading. In comparison to mere acrylic superstructures, a significant reduction of deformation and strain within metal-reinforced provisional restorations could be detected in FEM analysis. The advantages of the technique are: (1) reduction of treatment time for immediate temporization at stage 1 surgery; (2) predictable fixation and immobility of implants in the early stages of bone healing; and (3) less time spent for repairing provisional restorations as a result of no or less frequent fracture.

REFERENCES

1. Brånemark PI, Breine U, Adell R, Hanson BO, Linström J, Ohlsson A. Intraosseous anchorage of dental prosthesis. I. Experimental studies. *Scand J Plast Reconstr Surg* 1969; 3:81-100.
2. Albrektsson T, Brånemark PI, Hansson HA, Lindstrom J. Osseointegrated titanium implants. Requirements for ensuring a long-lasting, direct bone-to-implant anchorage in man. *Acta Orthop Scand* 1981; 52:155-170.
3. Brånemark PI. Osseointegration and its theoretical background. *J Prosthetic Dent* 1983; 50:399-410.
4. Donath K, Laass M, Gunzl HJ. The histopathology of different foreign-body reactions to oral soft tissue and bone tissue. *Virchows Arch A Pathol Anat* 1992; 420:131-137.
5. Ledermann PD. The new Ledermann screw. *Quintessenz* 1988; 5:1-17. (In German)
6. Schnitman PA, Wöhrle PS, Rubenstein JE. Immediate fixed interim prostheses supported by two-stage threaded

TABLE 6 Reduction of Strain and Deformation in Titanium Framework-Reinforced Acrylic Resin Provisional Restorations (%)



(A) Nonmetal reinforced. (B) Titanium framework reinforced.

- implants: methodology and results. *J Oral Implantol* 1990; 16:96–105.
7. Salama H, Rose LF, Salama M, Betts NJ. Immediate loading of bilaterally splinted titanium root-form implants in fixed prosthodontics. A technique reexamined: two case reports. *Int J Periodontics Restorative Dent* 1995; 15:345–361.
 8. Ledermann, PD. More than 20 years of experience with immediate loading of implant borne cantilever prostheses in the interforaminal region. *Z Zahnarztl Impl* 1996; 12:123–136.
 9. Chiapasco M, Gatti C, Rossi E, Haefliger W, Markwalder TH. Implant-retained mandibular overdentures with immediate loading. A retrospective multicenter study on 226 consecutive cases. *Clin Oral Implants Res* 1997; 8:48–57.
 10. Tarnow DP, Emtiaz S, Classi A. Immediate loading of threaded implants at stage 1 surgery in edentulous arches: ten consecutive case reports with 1- to 5-year data. *Int J Oral Maxillofac Implants* 1997; 12:319–324.
 11. Schnitman PA, Wöhrle PS, Rubenstein JE, DaSilva JD, Wang NH. Ten-year results for Branemark implants immediately loaded with fixed prostheses at implant placement. *Int J Oral Maxillofac Implants* 1997; 12:495–503.
 12. Balshi TJ, Wolfinger GJ. Immediate loading of Brånemark implants in edentulous mandibles: a preliminary report. *Implant Dent* 1997; 6:83–88.
 13. Whörle PS. Single-tooth replacement in the esthetic zone with immediate provisionalization: fourteen consecutive case report. *Pract Periodont Aesthet Dent* 1998; 10:1107–1114.
 14. Piattelli A, Corigliano M, Scarano A, Costigliola G, Paolantonio M. Immediate loading of titanium plasma-sprayed implants: a pilot study in monkeys. *J Periodontol* 1998; 69:321–327.
 15. Misch CE. Non-functional immediate teeth in partially edentulous patients: a pilot study of 10 consecutive cases using the Maestro dental implant system. *Compendium* 1998; 19:25–36.
 16. Jaffin RA, Kumar A, Berman CL. Immediate loading of implants in partially edentulous jaws: a series of 27 case reports. *J Periodontol* 2000; 71:833–838.
 17. Horiuchi K, Uchida H, Yamamoto K, Sugimura M. Immediate loading of Branemark system implants following placement in edentulous patients: a clinical report. *Int J Oral Maxillofac Implants* 2000; 15:824–830.
 18. Rocci A, Martignoni M, Gottlow J, Rangert B. Immediate function of single and partial reconstructions in the maxilla using MK IV fixtures. A retrospective analysis. *Appl Osseointegration Res* 2001; 2:22–26.
 19. Cooper LF, Rahman A, Moriarty J, Chaffee N, Sacco D. Immediate mandibular rehabilitation with endosseous implants: simultaneous extraction, implant placement and loading. *Int J Oral Maxillofac Implants* 2002; 17:517–525.
 20. Degidi M, Piattelli A. Immediate functional and non-functional loading of dental implants: a 2 to 60 months follow-up study of 646 titanium implants. *J Periodontol* 2003; 74:225–241.
 21. Degidi M, Piattelli A, Felice P, Carinci F. Immediate functional loading of edentulous maxilla: a 5-year retrospective study of 388 titanium implants. *J Periodontol* 2005; 76:1016–1024.
 22. Degidi M, Piattelli A. Comparative analysis study of 702 dental implants subjected to immediate functional loading and immediate non-functional loading to traditional healing periods with a follow-up of up to 24 months. *Int J Oral Maxillofac Implants* 2005; 20:99–107.
 23. Degidi M, Piattelli A. 7-year follow-up of 93 immediately loaded titanium dental implants. *J Oral Implantol* 2005; 31:25–31.
 24. Ivanoff CJ, Sennerby L, Lekholm U. Influence of initial implant mobility on the integration of titanium implants. An experimental study in rabbits. *Clin Oral Implants Res* 1996; 7:120–127.
 25. Hoshaw SJ, Brunski JB, Cochran GVB. Mechanical loading of Brånemark implants affects interfacial bone modeling and remodeling. *Int J Oral Maxillofac Implants* 1994; 9:345–360.
 26. Nkenke E, Lehner B, Weinzierl K, et al. Bone contact, growth, and density around immediately loaded implants in the mandible of mini pigs. *Clin Oral Implants Res* 2003; 14:312–321.
 27. Frost HM. The role of changes in mechanical usage set points in the pathogenesis of osteoporosis. *J Bone Mineral Res* 1992; 7:253–261.
 28. Piattelli A, Ruggeri A, Trisi P, Romasco N, Franchi M. A histologic and histomorphometric study of the bone reactions to non-submerged unloaded and loaded single implants in monkeys. *J Oral Implantol* 1993; 19:314–320.
 29. Piattelli A, Trisi P, Romasco N, Emanuelli M. Histological analysis of a screw implant retrieved from man: influence of early loading and primary stability. *J Oral Implantol* 1993; 19:303–306.
 30. Piattelli A, Corigliano M, Scarano A. Microscopical observations of the osseous responses in early loaded human titanium implants: a report of two cases. *Biomaterials* 1996; 17:1333–1337.
 31. Piattelli A, Corigliano M, Scarano A, Quaranta M. Bone reactions to early occlusal loading of two-stage titanium plasma-sprayed implants: a pilot study in monkeys. *Int J Periodontics Restorative Dent* 1997; 17:163–169.
 32. Piattelli A, Scarano A, Paolantonio M. Immediately loaded screw implant removed for fracture after a 15-year loading period: histological and histochemical analysis. *J Oral Implantol* 1997; 23:75–79.
 33. Degidi M, Scarano A, Piattelli M, Perrotti V, Piattelli A. Bone remodeling in immediately loaded and unloaded titanium dental implants: a histologic and histomorphometric study in humans. *J Oral Implantol* 2005; 31:18–24.
 34. Brunski JB, Moccia AF Jr, Pollack SR, Korostoff E, Trachtenberg DI. The influence of functional use of endosseous dental

- implants on the tissue-implant interface. I. Histological aspects. *J Dent Res* 1979; 58:1953-1969.
35. Brunski JB. Influence of biomechanical factors at the bone-biomaterial interface. In: Davies JE, ed. *The bone-biomaterial interface*. Toronto, Canada: Toronto University Press, 1991:391-405.
 36. Brunski JB. Forces on dental implants and interfacial stress transfer. In: Laney WR, Tolman DE, eds. *Tissue integration in oral, orthopaedic and maxillofacial reconstruction*. Chicago, IL: Quintessence, 1992:108-124.
 37. Brunski JB. Avoid pitfalls overloading and micromotions of intraosseous implants. *Dent Implantol Update* 1993; 4:77-81. (Interview)
 38. Cameron HU, Macnab I, Pilliar R. Porous surfaced vitallium staples. *S Afr J Surg* 1972; 10(2):63-70.
 39. Pilliar RM, Lee JM, Maniatopoulos C. Observations on the effect of movement on bone ingrowth into porous-surfaced implants. *Clin Orthop* 1986; 208:108-113.
 40. Brunski JB. Biomechanical factors affecting the bone-dental implant interface: review paper. *Clin Materials* 1992; 10:153-201.
 41. Szmukler-Moncler S, Salama H, Reingewirtz Y, Dubruille JH. Timing of loading and effect of micromotion on bone-dental implant interface: review of experimental literature. *J Biomed Mater Res* 1998; 43:192-203.
 42. Szmukler-Moncler S, Piattelli A, Favero GA, Dubruille JH. Considerations preliminary to the application of early and immediate loading protocols in dental implantology. *Clin Oral Implants Res* 2000; 11:12-25.
 43. Schnitman PA, Wohrle PS, Rubenstein JE. Immediate fixed interim prostheses supported by two-stage threaded implants: methodology and results. *J Oral Implantol* 1990; 16:96-105.
 44. Balshi TJ, Wolfinger GJ. Conversion prosthesis: a transitional fixed implant-supported prosthesis for an edentulous arch - a technical note. *Int J Oral Maxillofac Implants* 1996; 11:106-111.
 45. Misch CM. Immediate loading of definitive implants in the edentulous mandible using a fixed provisional prosthesis: the denture conversion technique. *J Oral Maxillofac Surg* 2004; 62(Suppl 2):106-115.
 46. Rodrigues AH, Morgano SM, Guimaraes MM, Ankly R. Laboratory-processed acrylic resin provisional restoration with cast metal substructure for immediately loaded implants. *J Prosthet Dent* 2003; 90:600-604.
 47. Zarone F, Apicella A, Nicolais L, Aversa R, Sorrentino R. Mandibular flexure and stress build-up in mandibular full-arch fixed prostheses supported by osseointegrated implants. *Clin Oral Implants Res* 2003; 14:103-114.
 48. Hobkirk JA, Schwab J. Mandibular deformation in subjects with osseointegrated implants. *Int J Oral Maxillofac Implants* 1991; 6:319-328.
 49. Saba S. Design of a cast bar reinforced provisional restoration for the management of the interim phase in implant dentistry. *J Can Dent Assoc* 1999; 65:160-162.
 50. Binkley JC, Irvin PT. Reinforced heat-processed acrylic resin provisional restorations. *J Prosthet Dent* 1987; 57:689-693.
 51. Emtiaz S, Tarnow DP. Processed acrylic resin provisional restoration with lingual cast metal framework. *J Prosthet Dent* 1998; 79:484-488.
 52. Burns DR, Beck DA, Nelson SK. A review of selected dental literature on contemporary provisional fixed prosthodontic treatment: report of the Committee on Research in Fixed Prosthodontics of the Academy of Fixed Prosthodontics. *J Prosthet Dent* 2003; 90:474-497.
 53. Hamza TA, Rosenstiel SF, Elhosary MM, Ibraheem RM. The effect of fiber reinforcement on the fracture toughness and flexural strength of provisional restorative resins. *J Prosthet Dent* 2004; 91:258-264.
 54. Longoni S, Sartori M, Davide R. A simplified method to reduce prosthetic misfit for a screw-retained, implant-supported complete denture using a luting technique and laser welding. *J Prosthet Dent* 2004; 91:595-598.
 55. Hruska AR. Intraoral welding of pure titanium. *Quintessence Int* 1987; 18:683-688.
 56. Mondani PL, Mondani PM. The Pierluigi Mondani intraoral electric solder. Principles of development and explanation of the solder using syncrystallization. *Riv Odontostomatol Implantoprotesi* 1982; 4:28-32.
 57. Hart RT, Hennebel VV, Thongpreda N, Van Buskirk WC, Anderson RC. Modeling the biomechanics of the mandible: a three-dimensional finite element study. *J Biomech* 1992; 25:261-286.
 58. Koriotoh TW, Romilly DP, Hannam AG. Three-dimensional finite element stress analysis of the dentate human mandible. *Am J Phys Anthropol* 1992; 88:69-96.
 59. Koriotoh TW, Hannam AG. Deformation of the human mandible during simulated tooth clenching. *J Dent Res* 1994; 73:56-66.
 60. Helkimo E, Carlsson GE, Helkimo M. Bite forces used during chewing of food. *J Dent Res* 1959; 29:133-136.
 61. Gibs CH, Mahan PE, Mauderli A, Lundeen HC, Walsh EK. Limits of human bite strength. *J Prosthet Dent* 1986; 56(2):226-229.
 62. Waltimo A, Könönen A. A novel bite force recorder and maximal isometric bite force values for healthy young adults. *Scand J Dent Res* 1993; 1001:171-175.
 63. Ferrario VF, Sforza C, Serrao G, Dellavia C, Tartaglia GM. Single tooth bite forces in healthy young adults. *J Oral Rehab* 2004; 31:18-22.
 64. Melo C, Matsushita Y, Koyano K, Hirowatari H, Suetsugu T. Comparative stress analyses of fixed free-end osseointegrated prostheses using the finite element method. *J Oral Implantol* 1995; 21:290-294.
 65. O'Brien WJ. *Dental materials and their selection*. 2nd ed. Germany: Quintessence, 1997.

66. Bratu E, Steigmann M. Analyse der strukturalen Spannungen zwischen Implantat und Knochen. *Implantologie J* 2003; 7:47–49.
67. Peters M, Leyens C, Kumpfert J. Titan und Titanlegierungen. Germany: DGM Deutsche Gesellschaft Für Materialkunde Verlag, 1996.
68. Wuebcken W. International plastic handbook for the technologist, engineer and user. 3rd ed. Munich, Germany/Vienna, Austria/New York: Hanser Publishers, 1995.
69. Lindquist LW, Rockler B, Carlsson GE. Bone resorption around fixtures in edentulous patients treated with mandibular fixed tissue-integrated prostheses. *J Prosthet Dent* 1988; 59:59–63.