

IMMEDIATE LOADING IMPLANTS: A CLINICAL REPORT OF 1301 IMPLANTS

Arturo Hruska, DDS
Paolo Borelli, DDS
Assia Chiaramonte Bordanaro, DDS
Eleonora Marzaduri, MD
Kurt-Lorenzo Hruska

KEY WORDS

Immediate loading
Osteointegration
Primary retention
Implants immobilization
Load sharing
Occlusion

The purpose of this study is to suggest 4 immediate load of implants techniques that are alternative and/or complementary to the traditional submersion technique. These techniques meet the criteria for implant immobilization during the entire period of osteointegration, and are based on the principles of splinting and load sharing. One hundred fifty-three maxillary and 309 mandibular arches were treated with 1301 implants. Only implants that satisfied the primary retention were immediately loaded with a provisional crown with wings (94), provisional plastic prosthesis (478), provisional plastic prosthesis with metal frame (293), and intraoral welding (436). Facies morphology, type of occlusion, size and function of the tongue, bone density, number, and length of implants appeared to have an influence on the results. Success rates achieved over 21 years are 99.3% with the intraoral welding machine, 98.3% with the provisional plastic prosthesis with metal frame, 97.9% with metal wings, and 88.02% with provisional plastic prosthesis. This last percentage is reflective of the years 1974 to 1984 when only blade-forms and root-forms with unscrewable abutments were available and a provisional plastic prosthesis was the only immobilization technique known. Guidelines are proposed for a treatment plan indicating when and why immediate loading implants can be suggested.

INTRODUCTION

In orthopaedics the traditional treatment of bone fractures is the immediate immobilization of bone. Although in the past this immobilization was obtained with plaster or a rigid splint, today the same type of immobilization can be achieved through osteosynthesis during 1-stage surgery (Figure 1).¹⁻⁸ This technique allows an immediate bone load and avoids muscle atrophy caused by long periods of immobilization.^{9,10} In orthopaedics, evidence-based medicine (EBM) estab-

lishes that immobilization is the only solution to obtain fracture healing. In dentistry, applying the same principle can result in successful osteointegration by immobilizing the implant.

The most common and traditional type of immobilization is the submersion of implants, but the disadvantage of this technique is that it is necessary to wait 3 to 4 months for osteointegration to occur before loading. Recently, there has been a reevaluation of the controlled immediate loading of implants as an alternative procedure.¹¹⁻¹⁹

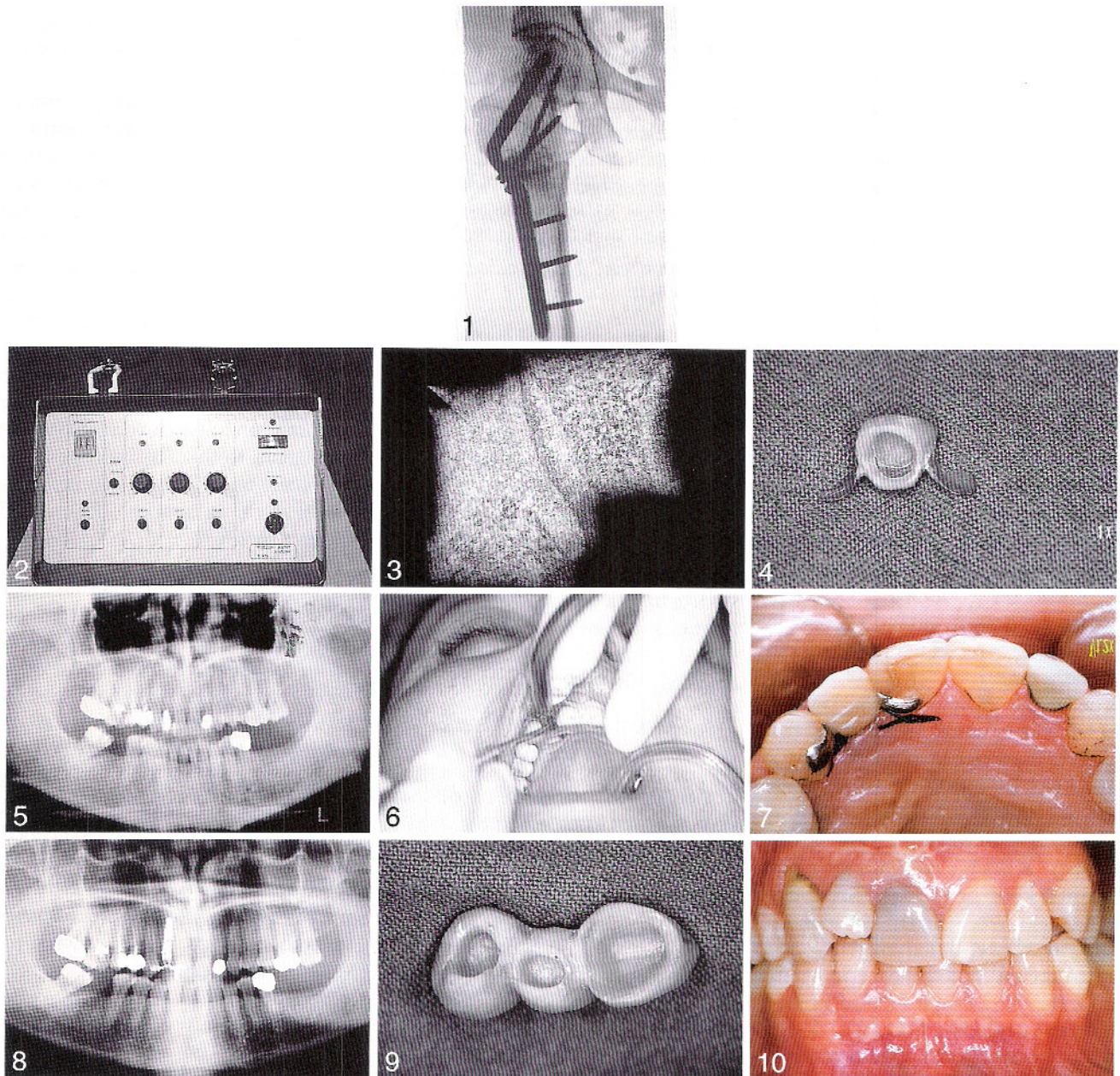
Arturo Hruska, DDS, is president of the Accademia Italiana di Stomatologia Implantoprotetica and is in private practice. Address correspondence to Dr Hruska at 10 Via G. Carducci, Rome, Italy, 00187 (E-mail: arturohruska@usa.net).

Paolo Borelli, DDS, is in private practice.

Assia Chiaramonte Bordanaro, DDS, is in private practice.

Eleonora Marzaduri, MD, is in private practice.

Kurt-Lorenzo Hruska is a dental student at the University of Rome.



FIGURES 1–10. FIGURE 1. X ray of an osteosynthesis. FIGURE 2. The Hruska intraoral welding machine. FIGURE 3. Metallographic microprobe image of pure titanium welding. FIGURE 4. Provisional crown with metal wings. FIGURE 5. Preoperative orthopantomography of the patient. FIGURE 6. Extraction of tooth number 1.2. The implant will be immediately inserted and the flap sutured. FIGURE 7. After relining, the provisional crown with metal wings is splinted to the adjacent teeth (1.1 and 1.3). FIGURE 8. Postoperative orthopantomography showing the immediately loaded implant and the provisional crown. FIGURE 9. Provisional plastic prosthesis. FIGURE 10. Preoperative facial view of the patient.

The aim of this article is to suggest 4 techniques for the immediate loading of implants, alternative, and/or complementary to the traditional submer-sion technique. These 4 techniques meet the criteria of implant immobilization during the entire period of osseointegration, and they are based on

the principles of splinting and load sharing.

MATERIALS AND METHODS

Patients

Between November 1974 and December 1995, 494 patients received a treat-

ment with an immediate load of implants. Of these patients, 73 were not included in this study because of the inability to follow-up at least 5 years after surgery. Causes of incompletion were patients' death, change of town or country (50% of the patients did not live in the city in which the research

was being conducted), and lack of compliance. Consequently, this study involved 421 patients, 151 women and 270 men ranging in age from 18 to 70 years, with the largest number (75%) between the ages of 40 and 65 years. One hundred fifty-three maxillary and 309 mandibular arches were treated, including 18 bimaxillary patients, with 1301 threaded implants. No implants are left unloaded as "sleepers." From 1974 to 1987 (14 years), only nonsubmergible implants were used.

Materials

We used blade-form titanium implants (Linkow, Oratronics, Hruska, SteriOss) and root-form titanium implants (Garbaccio, Hruska, Pasqualini, SteriOss without hex-lock, SteriOss with hex-lock).

The following immobilization techniques were used: provisional crown with plastic or metal wings; provisional plastic prosthesis (crown or bridge); provisional plastic prosthesis with metal frame; intraoral welding that foresees the use of titanium wire grade 1 or 2 (1.2–1.5 mm in diameter); and a Hruska intraoral welding machine (Figure 2). The intraoral welding machine is a device used for precision electrowelding with capacitive discharge and direct-current feed and features computer-based memory and programming systems for welding operations.^{20–24} Computer technology guarantees reproducibility. The design of the precision welding tool makes it particularly suitable for conducting welding operations within the oral cavity, in orthopaedics, or in other surgical fields. The instrument is a forceps-like device with conductive tips and is electrically insulated. Electrical current is supplied from a battery, thus avoiding voltage variations and ensuring perfect welds. The unit is manufactured in compliance with international safety standards for electro-medical devices. Although the temperature at the welding point is above 1600°C, there is no lateral heat transmission from the metal being joined. This is possible be-

cause of the design of the welding tool and the low thermal conductivity of titanium. The design of the machine ensures that there is no possibility of causing electric shock to the patient. It is important to note that the joining is not accomplished by the addition of other metals. As can be seen in the metalographic analysis, there is no oxidation between the 2 welded surfaces (Figure 3).²⁵

Preoperative preparation

In the first phase of treatment, before implant placement, temporary prostheses were completed. These were obtained from the patient's old dentures or from a new temporary one. In this case, impressions were taken and the shade selected. The laboratory technician manufactured temporary prostheses like traditional crown or bridge restorations before preparation. These served as temporary prostheses immediately after surgery.

Surgical and prosthodontics procedures

The quality and the quantity of bone at each site was assessed on the basis of reformatted computed tomographic (CT) scans.^{26,27} The technique of implant placement in bone has been described elsewhere.²⁸ Implants that did not move at full length under a force of 40 Nm, satisfied the primary retention, and were immediately loaded; the threaded straight or angled abutments were applied, and flaps were sutured. Temporary prostheses were then relined so that the abutment or abutments were immobilized by 1 of the following techniques:

1. A temporary plastic crown with metal or plastic wings was splinted to the adjacent teeth. It was cemented to the abutment with temporary cement and wings were splinted with a Maryland bridge bonding. This technique was adopted for the replacement of 1 or 2 front teeth (Figures 4 through 8).
2. A temporary plastic bridge for the

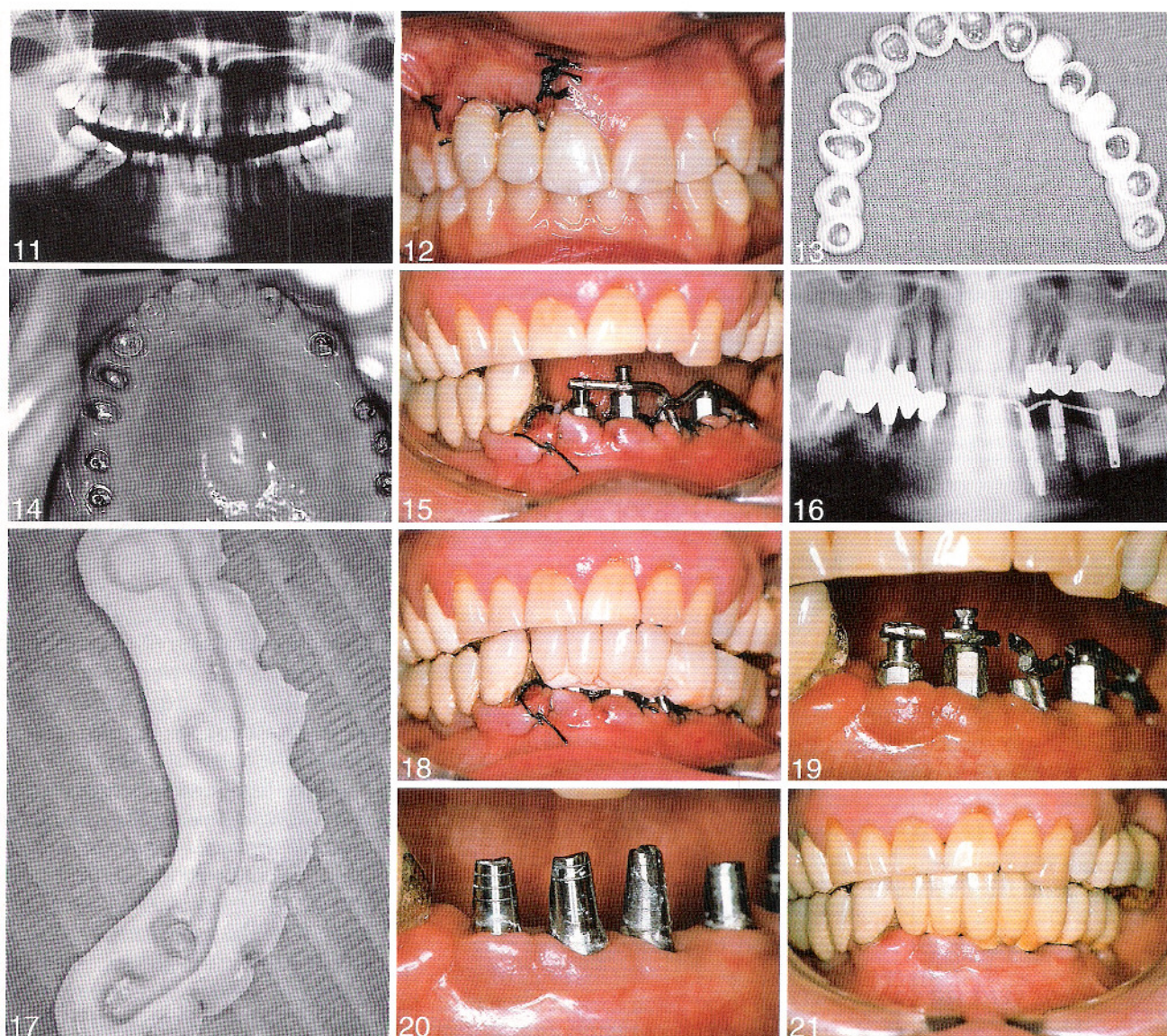
replacement of 2 or 3 contiguous teeth was used (Figures 9 through 12).

3. A metal-framed temporary bridge (to avoid fractures under load) was used. This technique was adopted when the area was not extended and partially or totally supported by implants (pontic; Figures 13 and 14). For both techniques, temporary prostheses were temporarily cemented in order to ensure stable splinting during the healing period.
4. The abutments were connected with the titanium wire by welding for partial or full-arch rehabilitation (4 or more teeth). The welding phase usually takes 7 to 10 minutes for a full arch restoration (Figures 15 through 18).

At that point, all implants were joined together into 1 mesostructure. Before relining the temporary prosthesis, all the undercuts were eliminated using wax or periodontal dressing (especially between the connecting wire and the soft tissue). After the temporary prosthesis was placed, occlusal adjustments were performed intraorally. During the bone healing or osteointegration period, which is typically 3 to 6 months in length in mandibular and maxillary cases, respectively, provisional prostheses were not removed, except for when the sutures were removed 1 week after surgery. After 3 to 4 months of osteointegration, temporary prostheses were removed (Figure 19).

Osteointegration of all the implants was then checked with all the available techniques. If this evaluation was positive, the technique for definitive abutments was adopted. Temporary prostheses worn during the healing period were adapted and relined on the shaped and paralalled new abutments in order to condition the surrounding soft tissues (Figure 20).²⁹

Once the soft tissues were conditioned, definitive crown or bridge work were performed in the traditional way (Figure 21). After the final restoration had been placed, an attempt was made



FIGURES 11–21. FIGURE 11. Preoperative orthopantomography showing bone resorption around teeth 1.2 and 1.3. FIGURE 12. Postoperative facial view of the patient. Teeth 1.2 and 1.3 were extracted and 2 implants were inserted. The temporary prosthesis was cemented on tooth 1.1 and on the implants immediately loaded. FIGURES 13 AND 14. A metal-framed temporary prosthesis has been placed for a full arch rehabilitation partially supported by implants. FIGURE 15. Immediate welding with titanium connecting wire of 5 implants in areas 36 to 41. FIGURE 16. Postoperative orthopantomography. FIGURE 17. Temporary prosthesis. FIGURE 18. Facial view of the patient showing the cemented temporary prosthesis. FIGURE 19. After 3 months, the wire is cut. FIGURE 20. The new abutments are parallelized. FIGURE 21. Final gold and porcelain restoration.

to see the patient at least every 6 months. All patients were examined for gingival health, adequate oral hygiene, occlusal relationships, implant stability, integrity and stability of the prostheses, and areas of excessive wear. If negative changes were found, the superstructure was removed, X rays were made, and the integration of each implant was evaluated.

RESULTS

Tables 1 and 2 summarize the data collected in this study and serve to illustrate the successes and failures of each technique in both arches (maxillary and mandible). Albrektsson et al³⁰ defined success of the implant as being when it is surrounded by compact or trabecular bone without radiolucency

and with bone loss of no more than 2 mm on calibrated radiographs. Ninety-four implants were immobilized with crowns with plastic or metal wings during the osteointegration period. Two implant failures occurred in 2 patients presenting a deep overbite.

Four hundred seventy-eight implants were immobilized with a temporary plastic prosthesis during the os-

TABLE 1

Study of 421 patients: 153 maxillae and 309 mandibles were treated with 1301 implants

	Provisional Crown With Wings	Provisional Plastic Prosthesis	Provisional Plastic Prosthesis With Metal Frame	Intraoral Welding
Number of implants followed in 5 years	94	478	293	436
Number of successes	92	425	288	433
Number of failures	2 (2.1%)	53 (11.08%)*	5 (1.7%)	3 (0.7%)

*Related to years 1974 to 1984 when only blade-form and root-form with unscrewable abutment implants were available and the provisional plastic prosthesis was the only immobilization technique known.

TABLE 2

Failure rates according to each technique between the 386 implants loaded in 153 maxillary arches and the 915 implants loaded in 309 mandible arches

	Provisional Crown With Wings	Provisional Plastic Prosthesis	Provisional Plastic Prosthesis With Metal Frame	Intraoral Welding
Failures in maxillary arch (%)	2.1	11.3	2.4	0.7
Failures in mandible arch (%)	2.1	10.98	1.4	0.64

teointegration period. With this technique 11.08% of the implants failed (53 implants). Of the 53 implant failures, 19 were due to luting failures and 21 due to fracture of the temporary restoration (during osteointegration period); 13 implants failed because of peri-implantitis after 1 to 2 years from the end of the treatment. In the 1970s, implant dentists used mostly blade implants, and the 53 failures we reported (corresponding to 11.08% of all implants performed with this technique) were consistent with the statistical data described worldwide at that time. Almost all of these failures were due to the fracture of the plastic temporary prostheses (the only technique available at that time) with loss of immobilization of the implant in the osteointegration period. We were strongly convinced that immobilization is the most important aspect of a successful implant therapy. This principle was confirmed using metal reinforced temporary prostheses to immobilize 293 root-form and blade-form nonsubmergible implants during the healing phase. Failures were reduced to 1.7% and were often related to partial luting fail-

ures in the first 60 to 90 days from surgery.

Four hundred thirty-six implants were immobilized with the intraoral welding machine. Three of these implants failed (0.7%). One failed after 1 year of loading because its neck fractured, and 2 failed between the second and the third year after surgery because of periimplantitis. The evidence in these 3 cases was a discrepancy of the number of implants placed (bone-implant interface) and muscular forces of the patients.

DISCUSSION

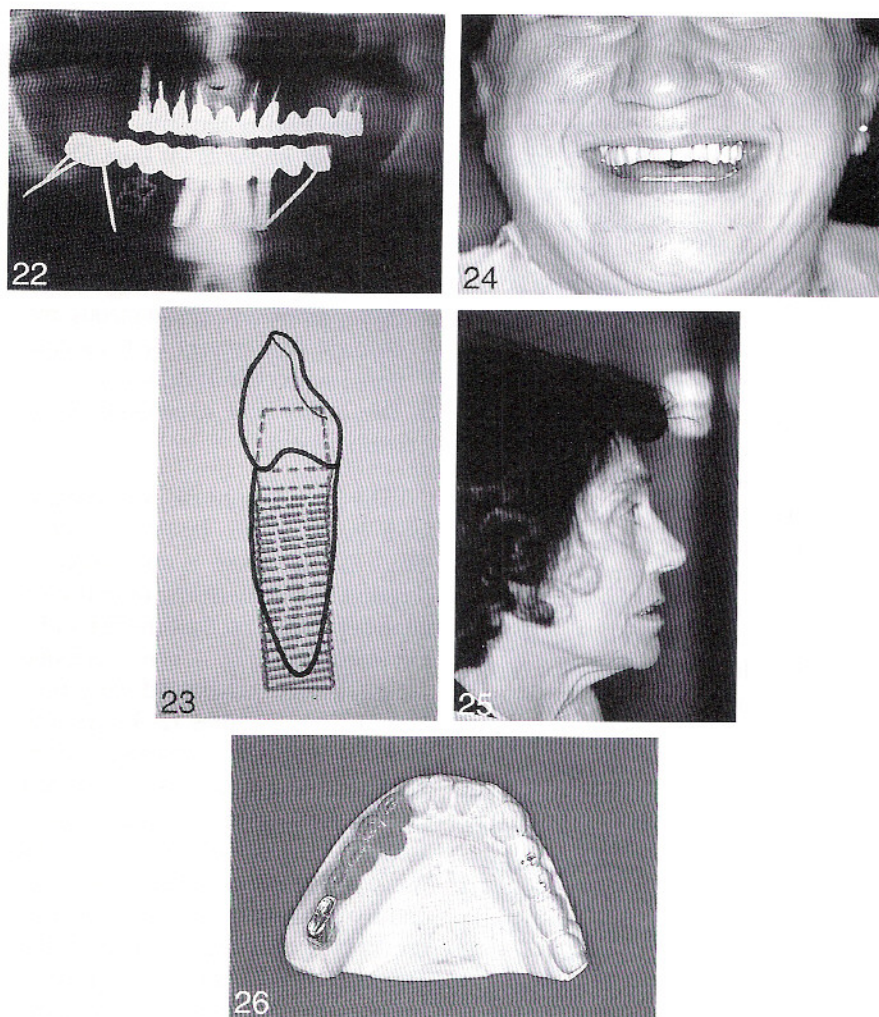
The initial studies³¹⁻³⁴ on success and failure in implant dentistry were related to root-forms and blades of different brands, but these statistical reports did not consider the causes of failure.

The longest term retrospective studies were done by Adell et al³¹ on Branemark implants, by Kapur,^{32,33} and by Schnitman et al³⁴ on Linkow blades. Adell et al³¹ reported 81% (maxilla) and 91% (mandible) survival rates after 9 years for root-form implants. James et al³⁵ criticized these statistical studies and showed how they were ar-

bitrarily misrepresented. Actually, Adell et al³¹ did not include all of the initial failures: those happening most frequently 1 year postsurgically and following the initial loading. James et al³⁵ corrected this data and found that the survival index in the Adell et al³¹ study was reduced to 70% in the maxilla and 76% in the mandible 5 years postsurgery. Kapur^{32,33} reported an 83% success rate after 42 months, and Schnitman et al³⁴ reported an 82.3% survival rate after 36 months, both including the initial failures.

In the early history of implant dentistry, submergible implants were not available because unscrewable abutments did not exist (Figure 22). Therefore all implants were in some way loaded.³⁶⁻⁴⁰ The immediate postsurgical immobilization of implants with unscrewable abutments presented a significant problem. Force created by the tongue was a major cause of failure during osteointegration. In the long-term edentulous ridge case, the sudden presence of the new implant abutment instinctively prompted the patient to frequently check its stability with the tongue during the first weeks after surgery, maybe due to a proprioceptive demand. Although there is no research on this subject, it has been described for centuries in the saying "the tongue ever turns to the aching tooth." The problem was solved initially by using a cemented temporary prostheses, and since 1984 with the use of the Hruska intraoral welding machine, both of which formed a splint.

Fourteen years of clinical experi-



FIGURES 22–26. FIGURE 22. Patient immediately loaded with Shalom implants in areas 46 to 47 and 35 (1969); a blade-form implant in area 43 (1986); root-form SteriOss implants in areas 33 (1991) and areas 41/42 and 31/32 (1992); and a 16-mm 3.5 Replace implant by SteriOss in area 14 (1999). FIGURE 23. Implant and the prosthetic crown must be considered a single element as in nature. FIGURES 24 AND 25. Difference between a patient with muscle hypertrophy and a patient without muscle hypertrophy. FIGURE 26. The occlusal anatomy of temporary prostheses during osteointegration should have an occlusal table reduced to one-third of the natural teeth (for posterior teeth).

ence with nonsubmergible implants (therefore immediately loaded) induced us to suggest 4 parameters (immobilization, force, resistance, fulcrum) that play a determinant role in the immediate load of implants, all based on the fundamental concept that implant and crown should be considered a unique element as in nature (Figure 23).^{41–43} The 4 parameters are immobilization, facies of the patient (force), implants (resistance), and crown and occlusion (fulcrum).

As in orthopaedics, lack of immo-

bilization of bone fragments in the fracture area is the cause of pseudoarthrosis. In implant dentistry any factor determining mobility of the implant during osteointegration induces the formation of peri-implant fibrous tissue.^{44–47} Micromotion or motion of the implant surface relative to the bone can result from functional overloading immediately after implantation.

A critical degree of micromotion caused by overload can result in fibrous repair, rather than osseous regeneration and osseointegration. Brun-

ski⁴⁸ theorized that 100 μ m of micromovements may be a critical level above which healing would undergo fibrous repair, rather than the desired osseous regeneration. Pilliar et al⁴⁹ suggested that movements of 28 μ m or less have no adverse effect on integration, whereas movement of 150 μ m or more results in fibrous connective apposition to the implant. As reported by Brunski,⁴⁸ Schnitman et al,⁵⁰ and Hahn,⁵¹ there is evidence that elimination of micromovements during the bone remodeling period may be the most important factor for osseointegration.

During the 1970s, the traditional procedure to avoid movements was splinting implants together or to the natural dentition in order to resist all tangential forces, especially those coming from the tongue, which was thought to be the major cause of failure during osteointegration at that time. Today, the concept of splinting in order to avoid micromovements is widely accepted.⁵²

In this study a provisional crown with plastic or metal wings was utilized to increase and better share the resistance to lingual trauma even when a single implant is placed. Katsuhiko et al⁵² reported the importance of immobilization to obtain osteointegration. Their findings showed that bilateral splinting action among several implants (that are themselves stable at placement) along with other stabilizing factors, such as optimal distribution of implants and a protective occlusal scheme, may resist micromovements at the bone-implant interface.

More recently, many implantologists have proposed immediate loading through a temporary prosthesis as a splinting method. This technique can be indicated for simple rehabilitations of a quadrant, but we strongly feel that in cases of extended reconstructions the intraoral welding gives the advantage of simplifying the application of the fixed temporary prosthesis because it overcomes the problem of disparallelism between the abutments. Further-

more, the intraoral welding becomes a mesostructure and avoids any risk of fracture or partial luting failure of the temporary prosthesis. It must be confirmed that partial luting failure and/or fracture of the temporary prosthesis will loosen immobilization of the implant under chewing and occlusal movements. If this happens during osseointegration, the implant can fail in a few days.

The facies (muscular mass) of the patient, which is related to the genetics, sex, and age of each individual, is to be carefully considered during the treatment plan because it represents the force. In fact, the treatment plan for a young patient with strong musculature will be totally different from the one of an elderly woman with muscular atrophy (Figures 24 and 25). Therefore, a few short implants can be successful for the elderly woman but will be a disaster for the young man mentioned above, for whom it is advisable to use the maximum number of implants as well as the longest and widest ones.

In nature, to all the forces (muscular, orthodontic, occlusal) applied to the tooth correspond a resistance offered by the root, the periodontal ligament, and the alveolar bone. The meeting point between forces and resistances (fulcrum) is the natural crown. Any force applied to the crown not corresponding to the barycentre of the root will move the whole tooth. This force can be controlled (orthodontics), and therefore harmless, or not controlled (wrong orthodontic treatment, occlusal trauma), and therefore noxious, causing root resorption or alveolar bone resorption.

The tongue of the patient must be carefully evaluated because it represents the strongest muscle per mass in the human body. Macroglossia and abnormal swallowing can produce displacement of the teeth and periodontal disease. Therefore, during the treatment plan open bites due to abnormal swallowing (anterior reconstructions) or macroglossia (posterior reconstruc-

tions) must be considered. The occlusion that is related to the opposing dentition (natural dentition, fixed prosthesis, partial or total denture) and to genetics (race and Angle's classes) should be considered when the treatment and the provisional prostheses are planned.

As we all know, the denture is tissue-supported. Therefore, any tangential force will be minimized through the displacement of the denture; there is a significant difference in biomechanics between patients using bilateral prostheses and patients with unilateral prostheses or with a denture.^{51,53} A good example of a treatment plan related to genetics is a case of a class II, 2° division, where it is impossible to avoid tangential forces; immediate load is therefore contraindicated except for when density of bone is D1 and implants are at least 16 mm long.

In implantology, to all the occlusal and muscular forces applied to the prosthetic crown there is a resistance offered by the implant and the peri-implant bone. The guideline that must be considered when implants are inserted is "to a given number of crowns supported by implants has to correspond an adequate bone-implant interface measurable in square millimeters" (Hruska and Borelli's law)⁴² in order to have a resistance that is proportioned to the forces applied. In other words, for the rehabilitation of the planned area, it is recommended to insert as many implants as possible compared to nature.

Primary implant retention is related to the following:

1. Bi- or tricortical contact of the implant. Katsuhiko et al⁵² and Ivanoff et al⁵⁴ reported that to maximize bicortical primary stabilization, the thin cortical bone of the nasal and antral floors were engaged when placing implants in the maxilla, with an increased number of implants osteointegrated even in the maxillary arch.
2. Bone density.^{55,56} Bone density is im-

- portant in the treatment plan of traditional implantology; it assumes an exponential value toward the immediate load of implants.⁵⁷
3. Length of implants (at least 12 mm long).
 4. Implant design. As reported by Koh,⁵⁸ threaded implants are favorable for immediate loading because they permit an instantaneous mechanical engagement of bone compared with cylindrical implants.
 5. The ability and experience of the oral surgeon.

The physiology base of immediate load is explained by Wolff's law,⁵⁹ which is that "there is apposition, resorption, and remodeling of trabecular bone depending on the direction of the forces applied to it." Current orthopedic guidelines recommend early function of limb fractures (2–3 days after surgery) and hip prostheses. These principles of orthopedics can be similarly applied to implantology: muscle activity improves oxygenation of the tissue in the fractured area of a femur, and the progressive immediate load on implants accelerates the healing process and calcification of the peri-implant tissue (Wolff's law).⁶⁰ The immediate immobilization of the implant and the occlusal anatomy of the temporary prosthesis correspond to the early function principles used in modern-day orthopedics.

The crown, as seen before, must be considered—as it is in nature—a unique element with its implant. On the crown there are areas on which forces applied by the muscular mass of the patient will concentrate. In immediate loading, if these forces fall outside of the concentric center of the implant, the osteointegration process will be seriously damaged. A temporary prosthesis, besides being an immobilization technique, represents the occlusion. The occlusal anatomy of temporaries during osteointegration should have an occlusal table reduced to a 1:3 ratio to natural teeth (as in regard to posterior teeth) in order to comply

with the function of occlusal stop, and at the same time to offer the least resistance to food during the masticatory function (Figure 26). If the patient has a strong musculature, a soft diet can be prescribed.

In cases of rehabilitation with 2 to 3 implants and strong natural abutments, it is recommended that adjustment of the occlusion of the temporary prosthesis on implants leaves only 1 contact in the centric position and all the contacts during lateral movements on the natural dentition. In cases of more extended and complicated rehabilitations, it is recommended that the temporary prosthesis be left with 1 contact in centric occlusion, reducing the angulation of the cusps and leaving all the contacts during excursive movements in the areas where the surgeon has applied the longest and/or largest implants to get the maximum bone-implant interface (crown/root ratio).

Implantology is often performed in conjunction with bone grafts. There is nothing worse for a bone graft than to permit a denture to press on it, which causes ischemia and displacement during the healing period. Immediate loading will not cause pressure on the soft tissue since the temporary prostheses are implant-borne. The authors, as well as others,⁵¹ recommend the avoidance of cantilevers because they represent an occlusal surface very far from the center of the implant.

Based on the results of this report and clinical observations, guidelines for an implant treatment plan are suggested: clinical and instrumental exams of the patient designed to analyze the facies; the type of occlusion; the size and function of the tongue (macroglossia, abnormal swallowing); the density of bone; and wall defects. Stable primary retention is the most important parameter for the choice of treatment. Immediate loading implants can be planned when bone density is D1 to D2, implants are longer than 12 mm, bone graft with the presence of only 1 wall defect.

Immediate loading will not be

planned and implants will be submerged to avoid failure of osteointegration when bone density is D4 without cortical support; ridge expansion is required; sinus grafts are required; bone grafts with wall defects are required; there is macroglossia; the patient is of the type II, 2° division angle class; the patient's medical status and overall health are compromised; and in posterior edentulous areas when aesthetics are not required, or for financial reasons.

CONCLUSION

Compared to orthopaedics, in which the aim of the therapy is a better and faster healing of a bone segment, in dentistry, loading an implant during the healing phase permits the bone to remodel and reorganize so that trabecular bone will displace and replace itself in relation to the forces to which it has been subjected. As such, it permits acceleration of the healing process and calcification of the peri-implant tissue (Wolff's law). An increase in bone density has been repeatedly observed upon re-entry of loaded implants.

The aim of this article has been to suggest a protocol that can be followed when an implant treatment plan is worked out. With the 4 techniques described, the implantologist can place implants where there is more available bone. Temporary and definitive prostheses are easily adapted to the osseous anatomy. This is a new concept in immediate loading that contrasts with actual treatment plans that still foresee the use of techniques in which the prostheses and mesostructures control the implant insertion.

ACKNOWLEDGMENTS

We wish to thank the laboratory technicians, Enzo Mutone (Naples, Italy) and Alessandro Valdinoci (Rome, Italy) for their help.

REFERENCES

1. Pogorzelski G, Mazurkiewicz Z, Szostakowski T, Borowik S. Polfix osteosynthesis in treatment of femoral

shaft fractures. *Chir Narzadow Ruchu Ortop Pol.* 1998;63:139-142.

2. Holst-Nielsen F. Treatment of femoral shaft fractures of the femoral shaft. *Acta Orthop Scand.* 1972;43:411-420.

3. Jozefaciuk D, Szojlew D. Results of surgical treatment of fractures of the femoral shaft. *Chir Narzadow Ruchu Ortop Pol.* 1971;36:7-12.

4. Ogden IA. Femoral shaft fractures. *J Pediatric Orthop.* 1995;15:1-2.

5. Niedziolka J. Intramedullary stable osteosynthesis of femoral shaft fractures by a closed method nailing. *J Bone Joint Surg (Br).* 1975;57:255.

6. Ruedi T. Primary osteosynthesis of femoral shaft fractures. *Helv Chir Acta.* 1984;50:611-615.

7. McLaughlin TP, Pillsbury SL. Internal fixation of femoral shaft fractures by a closed technique. *Conn Med.* 1984;48:9-13.

8. Waddell JP. Intramedullary rod fixation of femoral shaft fractures: comment. *Can J Surg.* 1990;33:255.

9. Phillips TW, Nguyen LT, Munro SD. Loosening of cementless femoral stems: a biomechanical analysis of immediate fixation with loading vertical, femur horizontal. *J Biomech.* 1991;24:37-48.

10. Huiskes R, Nunamaker D. Local stresses and bone adaptation around orthopedic implants. *Calcif Tissue Int.* 1984;36(Suppl 1):S110-117.

11. Chiapasco M, Gatti C, Rossi E, Haeffliger W, Markwalder TH. Implant-retained mandibular overdentures with immediate loading. A retrospective multicenter study on 226 consecutive cases. *Clin Oral Implants Res.* 1997;8:48-57.

12. Piattelli A, Corigliano M, Sciarano A, Costigliola G, Paolantonio M. Immediate loading of titanium plasma-sprayed implants: a histologic analysis in monkeys. *J Periodontol.* 1998;69:321-327.

13. Balshi TJ, Wolfinger GJ. Immediate loading of Branemark implants in edentulous mandibles: a preliminary report. *Implant Dent.* 1997;6:83-88.

14. Vassos DM. Immediate loading

of implants: an improved treatment of the elderly. *Dent Implantol Update*. 1996; 7:81-82.

15. Tarnow DP, Emtiaz S, Classi A. Immediate loading of threaded implants at stage 1 surgery in edentulous arches: ten consecutive case reports with 1-to-5-year data. *Int J Oral Maxillofac Implants*. 1997;12:319-324.

16. Salama H, Rose LF, Salama M, Betts NJ. Immediate loading of bilaterally splinted titanium root-form implants in fixed prosthodontics—a technique reexamined: two case reports. *Int J Periodont Rest Dent*. 1995;15:344-361.

17. Rosenlicht JL. Advanced surgical techniques in implant dentistry: contemporary applications of early techniques. *J Dent Symp*. 1993;1:16-19.

18. Ibbott CG, Oles RD. Immediate implant post-surgical complications. *J Can Dent Assoc*. 1995;61:193-198.

19. Hruska AR, Borelli P, Chiaramonte Bordonaro A, Marzaduri E. Carico immediato in impiantopotesi: indicazioni cliniche. *Dental Cadmos*. 2001;January:41-49.

20. Hruska A. Fusione in titanio e saldatura endorale. *Dent Moderno*. 1989; Marzo.

21. Hruska A. La saldatura intraorale di fusioni in titanio. *Dent Moderno*. 1986(IV);5:809.

22. Hruska A. Intraoral welding of pure titanium. *Quint Int*. 1987;10:683.

23. Hruska A. Intraorales Schweißen Von Reintitan. *Die Quintessenz*. 1988;1:35.

24. Hruska AR, Borelli P. Intra-oral welding of implants for an immediate load with overdentures. *J Oral Implantol*. 1993;19:34-38.

25. Wirz J, Schmidli F, Steinemann S, Wall R. Aufbrennlegierung im Spaltkorrosionstest. *SSO*. 1987;5:571.

26. Garg AK, Vicari A. Radiographic modalities for diagnosis and treatment planning in implant dentistry. *Implant Soc*. 1995;5:7-11.

27. Hruska A, Borelli P, Chiaramonte Bordonaro A, Marzaduri E. Revisione critica di tre tecniche implantari. Corso Monografico. *Il dentista Moderno*. 1996;4:45-61.

28. Bahat O. Treatment planning and placement of implants in the posterior maxillae: report of 732 consecutive Nobelpharma implants. *Int J Oral Maxillofac Implants*. 1993;8:151-161.

29. Toth RW, Parr GR, Gardner LK. Soft tissue response to endosseous titanium oral implants. *J Prosthet Dent*. 1985;54:564-567.

30. Albrektsson T, Zarb G, Worthington P, Eriksson AR. The long-term effect of currently used dental implants: a review and proposed criteria for success. *Int J Oral Maxillofac Implants*. 1996;11:379-386.

31. Adell R, Lekholm U, Rockler B, Branemark P. A 15-year study of osseointegrated implant in the treatment of the edentulous jaw. *Int J Oral Surg*. 1981;10:387.

32. Kapur KK. Veterans Administration Cooperative Dental Implant study—comparison between fixed partial dentures supported by blade vent implants and removable partial dentures. Part I: methodology and comparisons between treatment groups at baseline. *J Prosthet Dent*. 1987;499-513.

33. Kapur KK. Veterans Administration Cooperative Dental Implant study—comparisons between fixed partial dentures supported by blade-vent implants and removable partial dentures. Part IV: comparisons of patient satisfaction between two treatment modalities. *J Prosthet Dent*. 1991; 66:517-530.

34. Schnitman P, Rubenstein J, Jeffcoat M, et al. Blade implant clinical trial 36 month results. *J Dent Res*. 1987;66.

35. James R, Altman A, Clem D. A critical review of the osseointegrated literature. *NY State Dent J*. 1986;52:31.

36. Albrektsson T. Direct bone anchorage of dental implants. *J Prosthet Dent*. 1983;50:255-264.

37. Adell R, Lekholm U, Rockler B, Branemark PI. A 15-year study of osseointegrated implants in the treatment of the edentulous jaw. *Int J Oral Surg*. 1981;6:387-416.

38. Albrektsson T, Branemark P, Hansson HA, Lindstrom J. Osseointegrated titanium implants. Require-

ments for ensuring a long-lasting bone to implant anchorage in man. *Acta Orthop Scand*. 1977;52:155-161.

39. Branemark PI, Hansson BO, Breine U, Lindstrom J, Hallen O, Ohman A. Osseointegrated implants in the treatment of the edentulous jaw. Experience from a 10-year period. *Scand J Plast Reconstr Surg*. 1977;16:1-12.

40. Branemark P. Osseointegration and its experimental background. *J Prosthet Dent*. 1983;50:399-406.

41. Hruska A, Borelli P, Dietsh F. La terapia impiantopotesica negli anni '90. *Dent Moderno Maggio*. 1992;5: 79-114.

42. Hruska RA, Borelli P, Chiaramonte Bordonaro A. La biomeccanica nel piano di trattamento impiantopotesi. *Dossier, Dentista Moderno*. 1994; Aprile:5-32.

43. Hruska A, Borelli P. Implanto-logia. Sviluppi storici, approcci attuali, prospettive future. *Dent Mod*. 1994;10.

44. James R. The support system and the pergingival defense mechanism of oral implants. *J Oral Implantol*. 1987;6:270-277.

45. James RA. Connective tissue-dental implant interface. *J Oral Implantol*. 1988;4:607-616.

46. Luo Z, An KN. A theoretical model to predict distribution of the fabric tensor and apparent density in cancellous bone. *J Math Biol*. 1998;36: 557-568.

47. Burger EH, Klein-Nuland J. Microgravity and bone cell mechanosensitivity. *Bone*. 1998;22:127S-130S.

48. Brunski JB. Biomechanical factors affecting the bone-dental implant interface. Review paper. *Clin Mat*. 1992; 10:153-201.

49. Pilliar RM, Lee JM, Maniopoulos C. Observations on the effects of movement on bone ingrowth into porous-surfaced implants. *Clin Orthop*. 1986;208:108-113.

50. Schnitman PA, Wohrle PS, Rubenstein JE, Da Silva JD, Koch GC. Implants for partial edentulism. *J Dent Educ*. 1988;52:725-736.

51. Hahn J. Single stage, immedi-

ate loading, and flapless surgery. *J Oral Implantol.* 2000;26:193-198.

52. Katsuhiro H, Hiroya U, Kazuhiko Y, Masahito S. Immediate loading of Branemark system implants following placement in edentulous patients: a clinical report. *Int J Oral Maxillofac.* 2000;15:824-830.

53. Sagara M, Akagawa Y, Nikai H, Tsuru H. The effects of early occlusal loading on one-stage titanium alloy implants in beagle dogs. A pilot study. *J Prosthet Dent.* 1993;69:281-288.

54. Ivanoff CJ, Sennerby L, Lek-

holm U. Influence of mono- and bicortical anchorage on the integration of titanium implants. A study in the rabbit tibia. *Int J Oral Maxillofac Surg.* 1996;25:229-235.

55. Norton MR, Gamble C. Bone classification: an objective scale of bone density using the computerized tomography scan. *Clin Oral Implants Res.* 2001;12:79-84.

56. Misch CE. *Contemporary Implant Dentistry.* St. Louis: Mosby; 1993.

57. Bahat O. Branemark system implants in the posterior maxilla: clin-

ical study of 660 implants followed for 5 to 12 years. *Int J Oral Maxillofac Surg.* 2000;15:646-653.

58. Koh CS, Lee J, Choi K, Lee MS. Improved stress analyses of dental implant systems by homogenization technique. *J Oral Implantol.* 1997;23:67-74.

59. Wolf JH. Julius Wolff and his "law of bone remodeling." *Orthopade.* 1995;24:378-386.

60. Pazzaglia UE, Andrini L, Di Nucci A. The effects of mechanical forces on bones and joints. Experimental study on the rat tail. *J Bone Joint Surg Br.* 1997;79:1024-1030.