

> P. DIOTALLEVI¹, L. DAL CARLO², M.E. PASQUALINI², S. MAZZIOTTI³, M. NARDONE⁴, E. MOGLIONI²

¹Radiology Unit, Eosmed - Rome, Italy

²ARASS Association for research and social activities in Stomatology, Non profit Entity, Rome, Italy - Private practice

³Department of Radiological Sciences, University of Messina, Italy

⁴Department of Public Health, Ministry of Health, Rome, Italy

Radiological evaluation of long term complications of oral rehabilitations of thin ridges with titanium blade implants

TO CITE THIS ARTICLE

Diotallevi P, Dal Carlo L, Pasqualini ME, Mazziotti S, Nardone M, Moglioni E. Radiological evaluation of long term complications of oral rehabilitations of thin ridges with titanium blade implants. *J Osseointegr* 2014;6(1):11-14.

KEYWORDS Blade implants; Implant radiology; Oral implantology.

ABSTRACT

Aim The aim of this study was to assess the sensitivity of orthopantomography (OPT) in the diagnosis of long term complications in oral rehabilitations with blade implants.

Materials and methods A total of 235 blade implants in 189 patients, inserted between 1988 and 2003, were retrospectively analyzed. The records consisted of a first OPT taken between January and December 2010, and a second one 12 months after. The evaluation of implant health considered: integrity of the blade, normal radiological representation of the bone around the implant, dense and cortical appearance of bone around the implant collar. The evaluation of radiological complications considered: implant fracture, bone resorption around the implant, recession of the bone around the implant collar.

Results The sensitivity of the panoramic evaluation was equal to 100%. The complications detected were 5 cases of peri-implantitis, 9 cases of bone pericervical bone recession and 3 cases of fracture of the implant body. In cases of pericervical bone resorption the following radiological check up 12 months after the first one showed the progression of the disease in 6 out of 9 cases, with irreversible implant failure. In subjects with a radiological pattern of implant health there were no complications in the subsequent check up after 12 months. In the subjects with complications the specificity was equal to 100%.

Conclusion The radiographic evaluation by the means of OPT has shown high sensitivity in the diagnosis of long term complications of oral rehabilitations with blade implants and allows prompt therapeutic interventions. Radiological complications appeared mostly in the long term check ups and mainly consisted in recession of the bone around the neck or around the entire implant. More rarely implant fractures occurred, which, in the case of blades, sometimes were not associated with any clinical symptoms: therefore, post-surgical evaluation should not be separated from diagnostic imaging.

INTRODUCTION

The alveolar crest is defined as alveolar bone with a thickness lesser than 4 mm. This condition represents about 10% of the anatomical situations which an implantologist usually deals with (1, 2, 3).

Different surgical approaches exist for the rehabilitation of thin crests. Demolitive techniques, such as split crest, are based on the principle that the anatomy can be adjusted to the implant: the cortical bone tissue is fractured, usually at the vestibular level, in order to artificially create the space necessary to insert the screws (4, 5, 6, 7, 8, 9). Conservative techniques imply the use of thin implants, capable of penetrating between the two cortical bones, exploiting their stiffness to acquire stability. An example are blade implants, similar in shape to surgical scalpels, which are driven into the bone with a press fit technique, or rather with light percussions. Compared to screws, these implants are less used, though published data report similar results about their osteointegration, which always occurs (10, 11, 12, 13, 14, 15). However, blade implants are sometimes affected by complications whose prompt diagnosis is fundamental for implant survival.

The aim of this study was to evaluate the sensitivity of orthopantomography in the diagnosis of long term complications in oral rehabilitations with blade implants.

MATERIALS AND METHODS

For the study were retrospectively analyzed all patients who had previously been rehabilitated by the authors with blade implants (between 1988 and 2003) and who underwent long term radiographic control in the period between January and December 2010. The orthopantomographies of 189 subjects, 73

males and 116 females, with an average age of 68, were analyzed. The blade implants had been inserted by the authors in the period between 1988 and 2003 in patients with thin crests (thickness equal or less than 5 mm), as assessed by means of a CT scan in 118 cases, a surgical feeler gauge in 27 cases and intra-operative measurement in 44 cases (Fig. 1).

In total, 41 subjects underwent rehabilitations in the upper maxilla, with 43 blade implants of which 27 in the central sectors and 16 in the distal ones; 148 subjects underwent rehabilitations of the mandible, with a total of 192 blade implants, 18 of which in the distal zones and 12 in the central ones.

In all patients, due to the typical radiological artifacts generated by the blades in the CT scans, the post-surgical check-ups were carried out by means of orthopantomography (OPT). All the subjects whose implants had not been removed underwent a second orthopantomography after 12 months (between January and December 2011) in order to re-assess the reliability of the radiological indices through implant monitoring. Therefore, all radiographs were retrospectively analyzed.

The evaluation of implant health considered: integrity of the blade, normal radiological representation of the bone around the implant, dense and cortical appearance of bone around the implant collar. The evaluation of radiological complications considered: implant fracture, bone resorption around the implant, and recession of the bone around the implant collar (15, 20, 21).

All the subjects involved signed an informed consent form. The study was evaluated and approved by the Arass Ethical Committee.

RESULTS

The overall percentage of healthy implants was equal to 93.2% (219/235). In detail: up to 12 years after surgery, implant survival was 99% (102/103), while in the check up after more than 12 years, the percentage dropped to 86.3% (114/132). The complications detected were 5 cases of peri-implantitis, 9 cases of pericervical bone recession and 3 cases of fracture of the implant body. In 14 cases out of 17 there were signs of local phlogosis associated to pain.

In cases of pericervical bone recession the radiological check-up performed after 12 months showed the progression of the disease in 6 out of 9 cases, associated to hypermobility, with irreversible failure of the implant. These 6 patients included 4 who refused the therapeutic attempts (occlusal treatment and antibiotic therapy in the pocket) aimed to avoid blade failure. In treated subjects 3 out of 5 implants were still stable after 12 months.

In subjects whose radiographs showed healthy implants, neither clinical signs nor complications were detected at the following check up 12 months later. The sensitivity of OPT was therefore equal to 100%. In subjects with complications the specificity was equal to 100%.

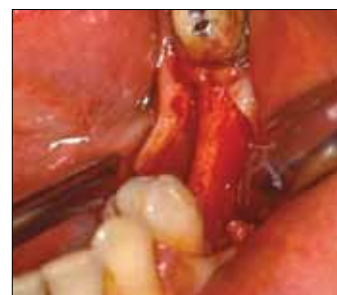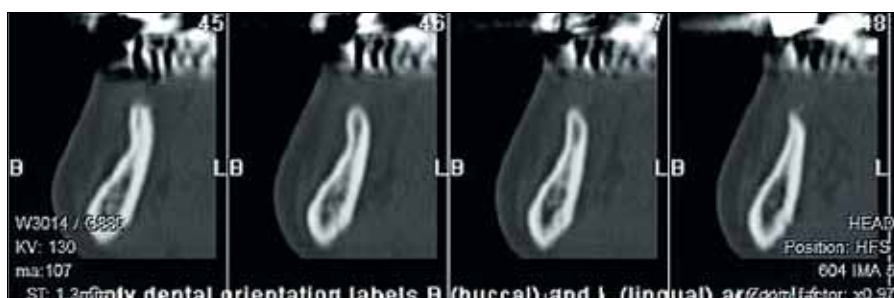


FIG. 1 TC image of a thin crest (1a) and corresponding anatomical appearance in the intraoperative image (1b).

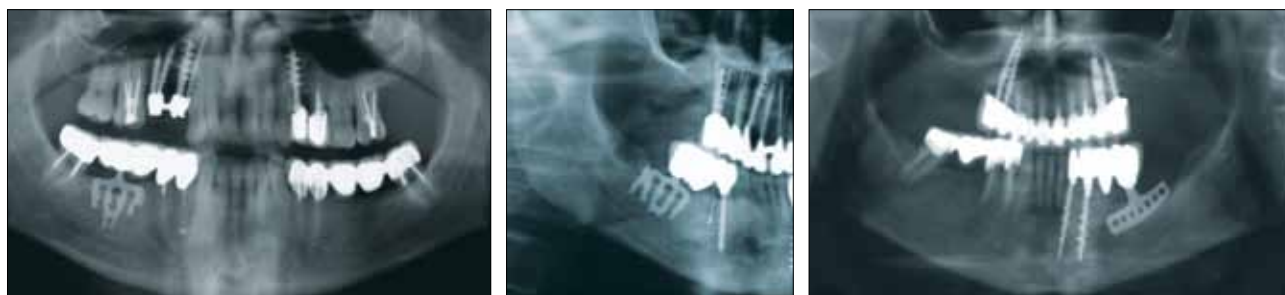

FIG. 2 Bone resorption around the neck of the blade, mild (a), moderate (b) and severe (c).

DISCUSSION

The long term X-ray evaluation of blade implants was carried out with orthopantomography, since these implants produce radiological artifacts in the TC scan, including those with 'cone beam' systems (22, 23, 24). Orthopantomography was highly reliable in the diagnosis of complications, with 100% sensitivity. This technique leads to prompt therapeutic interventions, which in some cases delay or prevent irreversible implant loss (25).

In the present retrospective study, it was observed that in 9 cases of pericervical bone recession the radiological signs were accompanied by the clinical detection of peri-implant pocket inflammation. Moreover, the radiographic signs of pericervical bone regression were mainly observed in the distal regions of the lower arch, that was the area where the implants are subjected to the greatest stress from a biomechanical point of view (26). Considering the development observed in our case series, we believe that such a finding clearly indicates the need for a new treatment, even if not immediately (as in the

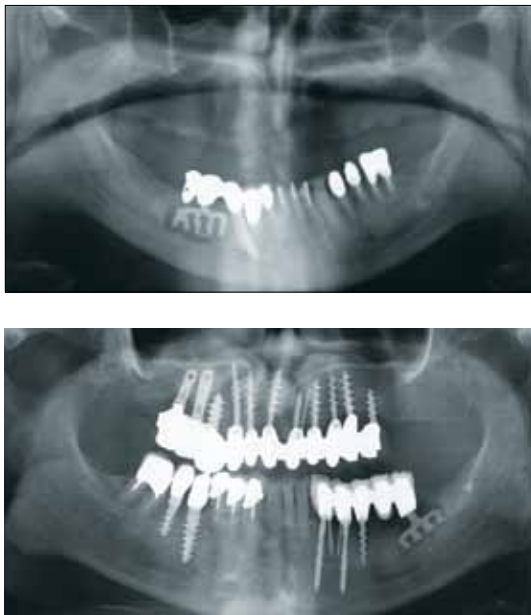


FIG. 3 Radiological appearance of peri-implantitis with bone resorption around the entire implant.

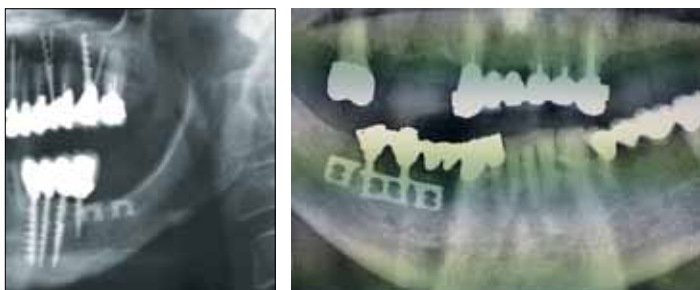

FIG. 4 Fracture of the blade implant, in correspondence of the collar (4a) and of the intra-osseous part (4b).

case of the peri-implantitis). An alteration of the pericervical bone must, in any case, be pointed out by the radiologist, so that immediate interventions aiming to heal the lesion can be performed (Fig. 2).

In the five cases in which bone rarefaction around the whole implant was radiographically observed, clinical examination always showed implant hypermobility, associated to local signs of phlogosis and pain when pressure was applied. In these situations the implant was immediately removed and replaced (Fig. 3). In 2 out of the 3 cases of implant fracture, both clinical examination and X-ray highlighted the fracture around the emerging collar, associated neither to phlogosis nor local pain, or to X-ray alterations of the peri-implant bone (Fig. 4a). In the third case, the fracture occurred in the endosseous part of the blade, an area not clinically evaluable and without any signs of local phlogosis; moreover, the stability of the fractured blade seemed to be maintained: such complication was therefore only visible through radiological examination which allowed the diagnosis of an otherwise asymptomatic fracture (Fig. 4b). This fracture was considered an adaptation of the implant to the local anatomy and physiology: moreover, it wasn't removed, since the amount of blade still intact continued to properly function.

In all cases radiographically analyzed, the cortical bone around the blade collar, as well as the peri-implant spongy bone appeared to be normal. This pattern was always combined with a clinical absence of pain, a correct peri-implant sounding and absence of implants mobility.

In this study mid term success rates resulted to be better than those reported in the literature for implant-supported rehabilitations obtained with split crest techniques; whereas in the long term, the results of the present study do not significantly differ from those reported by other authors (9, 27, 28, 29, 30).

CONCLUSION

Orthopantomography was highly reliable in the diagnosis of long-term complications in oral rehabilitations with blade implants, showing a sensitivity equal to 100% and allowing the prompt adoption of adequate

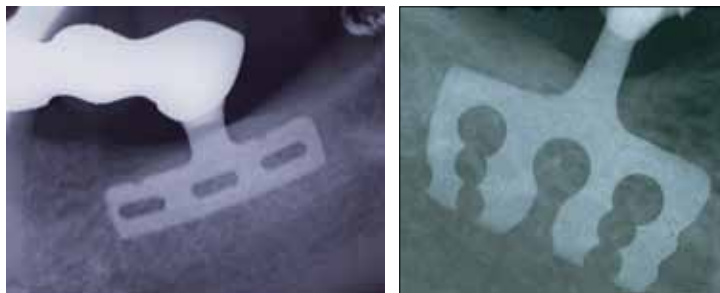


FIG. 5 Radiological pattern of normality in post-surgical check-ups (OPT details): regular representation of the cortical bone around the neck of the blade and of the peri-implant cancellous bone.

therapeutic interventions preventing irreversible implant failure. Radiological complications appeared mostly in the long term check-up and mainly consisted in recession of the bone around the neck or around the entire implant. More rarely implant fractures occurred, which, in the case of blades, sometimes were not associated with any clinical symptoms; therefore, post-surgical evaluation should not be separated from diagnostic imaging.

Compared with the data in the literature relating to rehabilitation using alternative techniques, such as the split crest, complications resulting from blade implants were less frequent in the 12 year check-ups: after that time the results do not differ significantly.

REFERENCES

- González-García R, Monje F, Moreno C. Alveolar split osteotomy for the treatment of the severe narrow ridge maxillary atrophy: a modified technique. *Int J Oral Maxillofac Surg* 2011; Jan;40(1):57-64.
- Sun JR, Kim SG, Moon SY, Lim SC, Ong JL. Histomorphometric analysis of delayed implantation after horizontal distraction osteogenesis of the mandible in dogs *Implant Dent* 2009 ;Oct;18(5):413-9.
- Fu JH, Wang HL. Horizontal bone augmentation: the decision tree. *Int J Periodontics Restorative Dent* 2011; Jul-Aug;31(4):429-36.
- Anitua E, Begoña L, Orive G. Controlled ridge expansion using a two-stage split-crest technique with ultrasonic bone surgery. *Implant Dent* 2012;Jun;21(3):163-70.
- Zijderveld SA, ten Bruggenkate CM, van Den Bergh JP, Schulten EA. Fractures of the iliac crest after split-thickness bone grafting for preprosthetic surgery: report of 3 cases and review of the literature. *J Oral Maxillofac Surg* 2004;Jul;62(7):781-6.
- Stellingsma C, Vissink A, Meijer HJ, Kuiper C, Raghoobar GM. Implantology and the severely resorbed edentulous mandible. *Crit Rev Oral Biol Med* 2004;Jul 1;15(4):240-8.
- Lew D, Amos EL, Shroyer JV. The use of a subperiosteal tissue expander in rib reconstruction of an atrophic mandible *J Oral Maxillofac Surg* 1988;Mar;46(3):229-32.
- Mardinger O, Minkow B, Tulchinsky Z. Augmentation of narrow ridges for implants rehabilitation--a review. *Refuat Hapeh Vehashinayim* 2002;Jul;19(3):62-70.
- Laster Z, Reem Y, Nagler R. Horizontal alveolar ridge distraction in an edentulous patient. *J Oral Maxillofac Surg* 2011;Feb;69(2):502-6.
- Linkow LI, Donath K, Lemons JE. Retrieval analyses of a blade implant after 231 months of clinical function. *Implant Dent* 1992 Spring;1(1):37-43.
- Di Stefano D, Iezzi G, Scarano A, Perrotti V, Piattelli A. Immediately loaded blade implant retrieved from a after a 20-year loading period: a histologic and histomorphometric case report. *J Oral Implantol* 2006;32(4):171-6.
- Proussaefs P, Lozada J. Evaluation of two vitallium blade-form implants retrieved after 13 to 21 years of function: a clinical report. *J Prosthet Dent* 2002 Apr;87(4):412-5.
- Trisi P, Quaranta M, Emanuelli M, Piattelli A. A light microscopy, scanning electron microscopy, and laser scanning microscopy analysis of retrieved blade implants after 7 to 20 years of clinical function. A report of 3 cases. *J Periodontol* 1993 May;64(5):374-8.
- Strecha J, Jurkovic R, Siebert T, Prachar P, Bartakova S. Fixed bicortical screw and blade implants as a non-standard solution to an edentulous mandible. *Int J Oral Sci* 2010 Jun;2(2):105-10.
- Pasqualini U. Endosseous implants. Protection of reparative osteogenesis with the "screw stump". *Dent Cadmos* 1972 Aug;40(8):1185-94.
- Berengo M, Fiorot M, Mazzuchin M. Retrieval of blade implants with piezosurgery: two clinical cases. *Minerva Stomatol* 2007 Jan-Feb;56(1-2):53-61.
- Thomson DH. Salvage of a blade-implant bridge. *Aust Dent J* 2001 Sep;46(3):216-219.
- Covani U, Marconcini S, Crespi R, Barone A. Immediate implant placement after removal of a failed implant: a clinical and histological case report. *J Oral Implantol* 2009;35(4):189-95.
- Smithloff M, Fritz ME. The use of blade implants in a selected population of partially edentulous adults. A 15-year report. *J Periodontol* 1987 Sep;58(9):589-93.
- Mattheos N, Janda MS. Exotic encounters with dental implants: managing complications with unidentified systems. *Aust Dent J* 2012;Jun;57(2):236-42.
- Reddy MS, Wang IC. Radiographic determinants of implant performance *Adv Dent Res* 1999 Jun;13:136-45.
- Telsey B, Oshrain HI, Joondeph NH, Mandel ID. Retrospective radiographic study of blade implants. *J Oral Implantol* 1991;17(2):140-5.
- Fanucci E, Leporace M, Di Costanzo G, Fiaschetti V, Simonetti G. Multidetector CT and dentascan software: dosimetric evaluation and technique improvement. *Radiol Med* 2006 Feb;111(1):130-8.
- Tyndall DA, Price JB, Tetradis S, Ganz SD, Hildebolt C, Scarfe WC. Position statement of the American Academy of Oral and Maxillofacial Radiology on selection criteria for the use of radiology in dental implantology with emphasis on cone beam computed tomography. *Oral Surg Oral Med Oral Pathol Oral Radiol* 2012 Jun;113(6):817-26.
- Pasqualini U, Pasqualini M. Uses and advantages of the dry self-molding varnish, Red Indicator, in selective impressions. *Dent Cadmos* 1982 Oct;50(10):49-63.
- Diotallevi P, Moglioni E, Pezzuti E. Correlazioni tra quadri radiologici e analisi biomeccaniche nel riassorbimento osseo pericervicale degli impianti orali. *Atti 45° Congresso SIRM*, 1-5-Giugno 2012: 277-278.
- Vanden Bogaerde L, Pedretti G, Dellacasa P, Mozzati M, Rangert B, Wendelhag I. Early function of splinted implants in maxillas and posterior mandibles, using Brånemark System Tiunite implants: an 18-month prospective clinical multicenter study. *Clin Implant Dent Relat Res* 2004;6(3):121-9.
- Noack N, Willer J, Hoffmann J. Long-term results after placement of dental implants: longitudinal study of 1,964 implants over 16 years. *Int J Oral Maxillofac Implants* 1999 Sep-Oct;14(5):748-55.
- García García A, Somoza Martín M, Gandara Vila P, Gandara Rey JM. A preliminary morphologic classification of the alveolar ridge after distraction osteogenesis. *J Oral Maxillofac Surg* 2004 May;62(5):563-6.
- Levin BP, Tawil P. Posterior tooth replacement with dental implants in sites augmented with rhBMP-2 at time of extraction--a case series. *Compend Contin Educ Dent* 2012 Feb;33(2):104-8.